



Australasian Gynaecological
Endoscopy & Surgery
Society Limited

AGES XXIV ANNUAL SCIENTIFIC MEETING 2014

27-29 March 2014
Hilton Sydney Australia

Tomorrow's Theatre Today Robotics. Instrumentation. Vision

International Faculty

Assoc. Prof. Pedro Escobar *Puerto Rico*
Assoc. Prof. Marit Lieng *Norway*
Dr Thomas Payne *USA*

PROGRAM & ABSTRACTS



stryker[®]
Platinum Sponsor of AGES

CONTENTS

Sponsors & Exhibitors	2
Welcome Message	3
Conference Faculty, Conference Committee & AGES Board Members	4
CPD and PR&CRM Points	6
Conference Program	
Thursday 27 March	5
Friday 28 March	7
Saturday 29 March	8
Program Abstracts	
Thursday 27 March	10
Friday 28 March	14
Saturday 29 March	18
Free Communications	
Thursday 27 March - Chairmen's Choice	21
Friday 28 March	27
Digital Communications	
Thursday 27 March Morning	32
Thursday 27 March Lunch	35
Thursday 27 March Afternoon	42
Friday 28 March Morning	44
Friday 28 March Lunch	47
Future AGES Meetings	54
Sponsor Information	54
Conference Information & Conditions	56



Bondi Beach

Sponsors and Exhibitors

AGES gratefully acknowledges the following sponsors and exhibitors:

stryker[®]

Platinum Sponsor of AGES

Applied
Medical 

Sponsor of AGES Meetings in 2014

 **DEVICE**
TECHNOLOGIES

Johnson & Johnson
MEDICAL

STORZ
KARL STORZ – ENDOSKOPE

Major Sponsors of the AGES XXIV Annual Scientific Meeting 2014

Exhibitors

Covidien
Gate Healthcare
Hologic
Olympus
Avant Mutual Group
Boston Scientific
ConMed
Gytech
High Tech Laser Australia
Sologyn
Sonologic
Sydney Adventist Hospital

WELCOME

Dear Colleague

Modern gynaecological surgery has embraced technological changes at a staggering rate. Never before have so many variations of techniques, instrumentation and entirely new procedures been available. Technological changes have required us all to keep pace with both the capacity to perform these procedures and the science that underpins their success – or their failure.

Consider that it is only 24 years since the first laparoscopic hysterectomy was reported and then consider the varied instruments used to take pedicles, improve vision and complete every aspect of the procedure laparoscopically. Now with the age of robotics upon us, this new tool needs to be assessed and learned having entered the Australasian marketplace.

Visual technology has brought about 3D camera systems, high definition picture quality and image capture systems that enable surgeons to perform better than ever before with the precision and clarity essential for the complex and prolonged pelvic surgery we now consider routine. Add to this a range of hysteroscopic instruments that simplify and automate many complex or uncommon procedures and surgeons have never had more choice in the operating room.

Reputed international stars Pedro Escobar from Puerto Rico, Marit Lieng from Norway and Thomas Payne from the USA will delight, surprise and present all manner of technologies from road-testing what we have now, to demonstrating live robotic surgery as it becomes more readily available in Australia and New Zealand. So many choices, so many operations, so many variations.

But what impact do all of these choices have on the outcomes for women? Do these far-reaching technologies impair rather than improve training? Can we convince ourselves (and our patients) that this vast array of dials and gadgets, tools and transformers are essential to their gynaecological care?


Of course, some surgical techniques come with bulletproof science to validate and substantiate these ideas and ideals, indelibly etched into the surgical marketplace. Other technologies have a less solid foundation with some, such as laser laparoscopy, falling almost completely from the landscape. So in keeping with AGES' promise to deliver the very latest in science, technology and gynaecological surgery, we welcome you to our 2014 Annual Scientific Meeting to dissect, discuss and demonstrate what we find in the operating room of today and tomorrow.



Dr Jim Tsaltas
President AGES



Assoc. Prof. Jason Abbott
Director AGES
Conference Chairman



Assoc. Prof. Harry Merkur
Hon. Secretary AGES
Scientific Co-Chair



Dr Stephen Lyons
Director AGES
Scientific Co-Chair



Sydney Harbour

CONFERENCE COMMITTEE

Assoc. Prof. Jason Abbott
 Assoc. Prof. Harry Merkur
 Dr Stephen Lyons
 Dr Jim Tsaltas
 Assoc. Prof. Anusch Yazdani
 Ms Michele Bender

Conference Chairman
Scientific Co-Chair
Scientific Co-Chair
Committee Members

INTERNATIONAL FACULTY

Assoc. Prof. Pedro Escobar
 Assoc. Prof. Marit Lieng
 Dr Thomas Payne

Puerto Rico
Norway
USA

AGES BOARD

Dr Jim Tsaltas
 Assoc. Prof. Anusch Yazdani
 Assoc. Prof. Harry Merkur
 Dr Stuart Salfinger
 Assoc. Prof. Jason Abbott
 Dr Keith Harrison
 Dr Stephen Lyons
 Dr Haider Najjar
 Prof. Ajay Rane OAM
 Dr Martin Ritossa
 Ms Michele Bender

President
Vice President
Honorary Secretary
Treasurer

Executive Director

AGES CONFERENCE ORGANISERS & SECRETARIAT

c/o Conference Connection
 282 Edinburgh Road
 CASTLECRAG
 SYDNEY NSW 2068
 AUSTRALIA
 P: +61 2 9967 2928
 F: +61 2 9967 2627
 E: conferences@ages.com.au

FACULTY

Assoc. Prof. Jason Abbott
 Dr Amy Arnold
 Dr Greg Cario
 Dr Danny Chou
 Dr Jenny Cook
 Mr Richard De Abreu Lourenço
 Dr Catherine Downs
 Prof. Robert Jansen AM
 Dr Gregory Jenkins
 Assoc. Prof. Alan Lam
 Dr Valeria Lanzarone
 Dr Michael Levitt
 Dr Stephen Lyons
 Dr Thomas Manley
 Dr Thomas Manolitsas
 Mr Scott Marinchek
 Assoc. Prof. Harry Merkur
 Dr Haider Najjar
 Dr John Pardey
 Dr Victoria Qin
 Dr Martin Ritossa
 Dr David Rosen
 Dr Mark Ruff
 Dr Stuart Salfinger
 Dr Jim Tsaltas
 Dr Justin Vass
 Dr Haryun Won
 Dr Clare Wong
 Dr Vivian Yang
 Assoc. Prof. Anusch Yazdani

New South Wales
New South Wales
New South Wales
New South Wales
New South Wales
New South Wales
New South Wales
New South Wales
New South Wales
New South Wales
New South Wales
Victoria
Victoria
New South Wales
New South Wales
Victoria
New South Wales
New South Wales
South Australia
New South Wales
New South Wales
Western Australia
Victoria
New South Wales
New South Wales
New South Wales
New South Wales
Queensland



The Rocks

DAY 1

Thursday 27 March 2014

0730-0800 Conference Registration

Hilton Sydney
Level 3 Ballroom

0800-0810 Introduction and Welcome *J Tsaltas, J Abbott*

0810-1030 **SESSION 1** *Sponsored by Stryker*
Techniques and Technology in Minimally Invasive Gynaecological Surgery

Chairs: *J Tsaltas, J Abbott*

0810-0830 Robot-assisted gynaecological surgery
T Manolitsas

0830-0850 Is Natural Orifice Transluminal Endoscopic Surgery (NOTES) to the patient's advantage?
M Ritossa

0850-0910 Power and the Passion – harnessing energy for minimally invasive surgery
S Lyons

0910-0930 Technological challenges in small spaces – intrauterine transformation
H Won

0930-1000 Panel discussion and questions from the floor
Transponder Session
Moderators: *J Tsaltas, J Abbott*
Panel: *S Lyons, T Manolitsas, M Ritossa, S Salfinger, H Won*

1000-1030 **Keynote Lecture**
Chair: *A Yazdani*
Robot-assisted hysterectomy – the large uterus
T Payne

1030-1100 Morning Tea and Trade Exhibition

Digital Communications Presentations and Adjudication

1030 Surgical training in gynaecology; the past, present and future
Acton J, Salfinger S

1035 How to avoid and manage catastrophic vascular bleeding during laparoscopy
Lam A, Ford R, Almotrafi T, Mangat M, Salama Y, Ford S

1040 Strategies and methods to overcome difficult laparoscopic tissue retrieval
Lam A, Khong SY, Ford R, Morris A, Almotrafi T, Mangat M

1045 Appendicitis in pregnancy
Berlund P, Jeyarajan E, Pulhalla H, Fleming T

1100-1230 **SESSION 2** *Sponsored by Applied Medical*
Making Dollars and Sense
Chairs: *D Chou, H Won*

1100-1120 An entrepreneur's guide to taking your product to market
S Marinchek

1120-1135 Success and failure in the gynaecological business place
J Abbott

1135-1150 Costing technology and patient outcomes – making sense of the dollars
R De Abreu Lourenço

1150-1200 Questions

1200-1230 **Keynote Lecture**
Chair: *S Salfinger*
Intrauterine pathology: the evidence for diagnosis and management
M Lieng

1230-1330 Lunch and Trade Exhibition

Digital Communications Presentations and Adjudication

1230 Laparoscopic E/O ultralow rectal endometriosis
Lam A, Almotrafi T

1235 A novel approach to robotic sacral hysteropexy
Al-Salibi S, Carey M

1240 The first Australian robotic-assisted tubal anastomosis
Ang WC, Marshall B

1245 A robotic-assisted resection of Stage IV colorectal endometriosis
Ang WC, Bell S

1250 Isolated sciatic nerve endometriosis: laparoscopic excision of a 3cm lesion
Chou D, de Rosnay P, Possover M, Cario G, Rosen D, Reyftmann L, Cook J, Choi S, Tsai B, McKenna J, Kanade J

1255 Non-puerperal uterine inversion due to endometrial carcinoma: case report and review of the literature
Kapurubandara S, Hogg R

1300 Laparoscopic retrieval of an intraabdominal Mirena
Ratner R, Tsaltas J, Najjar H, Manley T

1305 Total laparoscopic hysterectomy made easier with new utero-vaginal manipulator
Titiz H

1310 Tips and tricks on how to avoid injuries during laparoscopic sacro-colpo/hysteropexy
Titiz H

1315 Laparoscopic intramural myomectomy – recorded with 3D laparoscope
McKenna J, Tsai B, T Kanade, S Choi, L Reyftmann, G Cario, D Rosen, D Chou

1320 Robot-assisted hysterectomy – recorded in 3D
Tsai B, Kanade T, McKenna J, Choi S, Reyftmann L, Cario G, Rosen D, Chou D

1330-1500 **SESSION 3** *Sponsored by Applied Medical*
Free Communications
Chairmen's Choice
Chairs: *J Abbott, S Lyons, H Merkur*

1330-1340 The SWEC Uterine Artery Manoeuvre during TLH – bringing the target to the instrument
Tsai B, Kanade T, McKenna J, Choi S, Reyftmann L, Cario G, Rosen D, Chou D

1340-1350 Single site robotic hysterectomy : a personal journey
Chan F

1350-1400 Clinical audit resource: an operative data form for gynaecological endoscopic procedures at the Aga Khan University Hospital, Nairobi.
Dodia RH, Obura T, Muchiri D

DAY 1

Thursday 27 March 2014
continued

- 1400-1410** Myosure resection of endometrial polyps under local anaesthesia in the outpatient setting: A prospective study *McIlwaine P, McElhinney B, Karthigasu K*
- 1410-1420** The role of 'sensory substitution' or 'visual haptics' in robotic surgery *Kanade T, McKenna J, Tsai B, Choi S, Reyftmann L, Chou D, Rosen D, Cario G.*
- 1420-1430** Implication of umbilical port and endoscope size on total laparoscopic hysterectomy: A randomized control trial *Acton J, Salfinger S, Tan J*
- 1430-1440** Obstetric outcomes following laparoscopic transabdominal cervical cerclage *Ades A, May J, Cade TJ, Umstad M*
- 1440-1450** Mesh erosion with laparoscopic mesh sacrocolpopexy with and without hysterectomy. A new non classical "Y" graft technique makes all the difference *McKenna J, Tsai B, Kanade T, Reyftmann L, Chou D, Rosen D, Cario G*
- 1450-1500** A prospective case-control study to examine for the presence of nerve fibres in the endometrium and the usefulness of endometrial biopsy as a diagnostic test for endometriosis *Ellett L, Readman E, Newman M, McIlwaine K, Villegas R, Jagasia N, Maher P*

1500-1530 Afternoon Tea and Trade Exhibition

Digital Communications Presentations and Adjudication

- 1500** Developing and implementing a mandatory evidence-based laparoscopy curriculum for residents at the Royal Women's Hospital *Connell E, Schreuder HWR, Van de Weijer P, Ang WC*
- 1505** A retrospective review of all cases of leiomyosarcoma referred to The Royal Women's Hospital over a five-year period *Connell E, Gu Y, McNally O, Ang WC*
- 1510** Tuboovarian abscess as primary presentation for imperforate hymen *Wen Ho J, Angstetra D, Loong R, Fleming T*
- 1515** Laparoscopic management of adhesions from silent chemical peritonitis in a case of primary ovarian dermoid cyst *McKenna J, Kanade T, Tsai B, Choi S, Reyftmann L, Rosen D, Chou D, Cario G,*

1530-1715 **SESSION 4** Sponsored by Device Technologies
**Robotic Surgery in the Pelvis:
How Far Can You Go?**
Chairs: *H Najjar, D Garza*

1530-1545 **Becoming accredited in robot-assisted surgery – AGES and the College**
J Tsaltas

1545-1600 **Mini-laparoscopy, LESS, robotic single site and the next frontier in minimally invasive surgery**
P Escobar

1600-1615 **And this little piggy went wee, wee, wee, all the way home – a urological robotic story**
J Vass

1615-1630 **Robot-assisted reduced port hysterectomy: dual site and single site**
T Payne

1630-1715 **Spoilt for choice – which surgical mode to use and when?**
Transponder Session
Panel discussion
Moderators: *A Yazdani, H Merkur*
Panel: *J Vass, D Chou, T Payne, M Lieng, P Escobar, A Lam*

1715-1815 **Welcome Cocktail Reception**
Hilton Sydney

CPD and PR&CRM POINTS

Full attendance (Thursday 27 March, Friday 28 March and Saturday 29 March)	19 CPD points
Thursday 27 March only	7 CPD points
Friday 28 March only	7 CPD points
Saturday 29 March only	4 CPD points

Attendance by eligible RANZCOG Members will only be acknowledged following signature of the attendance roll each day of the Conference, and for each workshop. The RANZCOG Clinical Risk Management Activity Reflection Worksheet (provided in the Conference satchel) can be used by Fellows who wish to follow up on a meeting that they have attended to obtain PR&CRM points. This worksheet enables you to demonstrate that you have reflected on and reviewed your practice as a result of attending a particular workshop or meeting. It also provides you with the opportunity to outline any follow-up work undertaken and to comment on plans to re-evaluate any changes made. Fellows of this College who attend the Meeting and complete the *Clinical Risk Management Activity*

Reflection Worksheet in accordance with the instructions thereon can claim for an additional 7 PR&CRM points for the Meeting. For further information, please contact the College.

DAY 2

Friday 28 March 2014

Level 3 Ballroom

0815-1030 **SESSION 5** *Sponsored by Stryker*

Live Surgery

Transmitted from Westmead Private Hospital

Moderators: *G Cario, J Cook, J Pardey, D Rosen*

0845-1030 **Live Surgery Transmission**

Robot-assisted hysterectomy - multiport *P Escobar*

Robot-assisted hysterectomy - single site *T Payne*

Evidence for robotics

Robot-assisted hysterectomy & myomectomy *V Qin*

Robot-assisted gynaecological oncology *A Arnold*

Robot-assisted pelvic floor surgery *C Wong*

1030-1100 **Morning Tea and Trade Exhibition**

Digital Communications Presentations and Adjudication

1030 Robotic Burch colposuspension: rise of the machines!

Kanade T, McKenna J, Tsai B, Choi S, Reyftmann L, Chou D, Rosen D, Cario G

1035 Bone in the uterus *Kong K, Kanade T, Tsai B, McKenna J,*

Choi S, Reyftmann L, Rosen D, Cario G, Chou D

1040 Combining mini-laparotomy and laparoscopy for the large ovarian cyst – a retrospective case series *Li J, Tan J, Gannon E*

1045 Laparoscopic management of late acute vault abscess & irreducible vault eversion 3 years after anterior mesh repair *McKenna J, Kanade T, Tsai B, Reyftmann L, Chou D, Rosen D, Cook J, Cario G*

1050 To evaluate the role of pre-operative Transvaginal Ultrasound (TVS) to predict appropriate surgical route for the management of women with adnexal mass. *Menakaya UA, Reid S, Shetty Y, Infante FI, Lu C, Condous G*

1100-1230 **SESSION 6** *Sponsored by Karl Storz Endoscopy*

Scared by the Scar: Caesarean Scars at Surgery

Chairs: *D Garza, R Deans*

1100-1115 **Scars and early pregnancy: ectopics and infertility**

A Yazdani

1115-1130 **One layer or two?**

M Lieng

1130-1145 **Caesarean scars and hysterectomy – using technology to optimise outcomes**

V Yang

1145-1200 **Questions**

1200-1230 **Keynote Lecture**

Chair: *A Rane*

The retroperitoneum: not only for the oncologist

P Escobar

1230-1330 **Lunch and Trade Exhibition**

Digital Communications Presentations and Adjudication

1230 Prediction of pod obliteration using the real time dynamic sliding sign - a review of 200 cases undergoing laparoscopy *Menakaya UA, Reid S, Lu C, Infante FI, Condous G*

1235 In women with normal POD and no posterior compartment deep infiltrating endometriosis, can we use the soft marker, site-specific tenderness at TVS, in the pre-operative mapping of peritoneal endometriosis *Reid S, Menakaya U, Lu C, Infante FI, Condous G*

1240 Platelet rich plasma and CO2 laser treatment of vaginal atrophy and dyspareunia: a pilot study *Behnia-Willison F, Miller B, O'Shea R, Seman E, Turnbull L, Rezaei-Motlagh A.*

1245 Women's attitudes and expectations towards trans-vaginal NOTES from East to West *Behnia-Willison F, Johns K, Behnia L, Mirzakhani P, Jourabchi A, Sarmadian M, Garg A, Miller B, Rezaei-Motlagh A*

1250 Management of major haemorrhage and conversion to open surgery at laparoscopic hysterectomy *Muttusamy J, Qin V, Merkur H*

1255 Invasive Group A Streptococcus infection in O and G patients at Sydney metropolitan hospitals *Qin V, Wong C, Blumenthal N, Haldas G, Nikam Y, Yang V, Merkur H, Haghighi K*

1300 Major vascular injury at laparoscopy: do we need a surgical drill? *Qin V, Merkur H, Harris A*

1305 Decrease in AMH after laparoscopic excision of endometrioma *Rodgers R, Reid G, Cooper M, Tsaltas J*

1310 A horn too many – the total laparoscopy in the management of uterine anomalies *Thevathasan J, Myers C, De Luca L, Sherwood R*

1315 Effect of obesity on outcomes in gynaecological laparoscopic procedures *Wong WL, Ho JW, Fleming T*

1330-1500 **SESSION 7**

Free Communications

Chairs: *P Maher, R O'Shea*

1330-1339 Survey to assess current practice and factors effecting clinicians' decision to perform opportunistic bilateral salpingectomy during gynaecological surgery for benign disease *Kapurubandara S, Qin V, Anpalagan A, Merkur H, Wain G, Brand A, Hogg A*

1339-1348 Use of ureteric catheter (lighted and non-lighted) in challenging cases *Titiz H*

1348-1357 Hysterectomy and endometrial hyperplasia: outcome and management, clinical experiences at SWAPS *Qin V, Merkur H*

1357-1406 A novel method to facilitate uterine delivery at robotic hysterectomy *Manolitsas T*

DAY 2
Friday 28 March 2014
continued

- 1406-1415 Setting the table: A practical guide to robotic docking from the SWEC experience *Tsai B, Choi S, McKenna J, Kanade T, Reyftmann L, Cario G, Rosen D, Chou D*
- 1415-1424 Hysteroscopic resection of complete uterine septum in two cases with different presentations – 'scope of the resectoscope' *Kanade T, McKenna J, Tsai B, Choi S, Reyftmann L, Rosen D, Cario G, Chou D*
- 1424-1433 An ultrasound based staging system as a preoperative triage tool for laparoscopic treatment of endometriosis *Menakaya UA, Reid S, Lu C, Infante F, Condous G*
- 1433-1442 Robotic assisted laparoscopic segmental cystectomy, for deeply infiltrating endometriosis of the bladder *Manley J, Tsaltas J, Harewood L, Berkowitz E*
- 1442-1451 Cervical cerclage - 100 years on, time to mainstream a laparoscopic approach? *McKenna J, Kanade T, Tsai B, Cook J, Rosen D, Chou D, Cario G*
- 1451-1500 Travelling Fellowship Presentation *Hugo Fernandez*

1500-1530 Afternoon Tea and Trade Exhibition

- 1530-1600 **The Perpetual Dan O'Connor Lecture**
Chair: *A Lam*
How technology has changed the world of fertility *R Jansen*
- 1600-1645 **SESSION 8** *Sponsored by Johnson & Johnson Medical*
Blood is Bad
Chairs: *M Ritossa, S Lyons*
- 1600-1615 Medical management of horrific haemorrhage
T Manley
- 1615-1630 Critical management of the shocked patient
C Downs
- 1630-1645 Questions and discussion

1700 **AGES Annual General Meeting**

1930 for 2000

Gala Dinner
Catalina Lyne Park, Rose Bay
Complimentary coach transfers provided.
Please assemble in the hotel foyer at 1845.

DAY 3
Saturday 29 March 2014

- 0830-1000 **SESSION 9** *Sponsored by Stryker*
The Surgeon's Toolbelt
Chairs: *A Rane, G Hardas*
- 0830-0845 Single site surgery devices *H Najjar*
- 0845-0900 Visionary changes in surgery (3D cameras)
H Merkur
- 0900-0915 iSurgery *M Ruff*
- 0915-0930 Sonographic advances that change the way surgeons view surgery
V Lanzarone
- 0930-0945 Cool tools that we could use: can we borrow that?
S Salfinger
- 0945-1000 Questions

1000-1030 Morning Tea and Trade Exhibition

- 1030-1315 **SESSION 10** *Sponsored by Device Technologies*
Sharing Technologies in an Ever-Changing World
Chairs: *J Tsaltas, R O'Shea*
- 1030-1100 Cost and robot-assisted surgery in gynaecology – a complex problem
P Escobar
- 1100-1130 Simulation stimulation – educating in a technological world
M Lieng
- 1130-1200 The successful robotic program: building it step by step
T Payne
- 1200-1300 **Debate**
Moderators: *J Tsaltas, A Yazdani*
That robot-assisted laparoscopy will replace conventional laparoscopy
For: *T Manolitsas, D Rosen*
Against: *G Jenkins, M Levitt*
- 1300-1315 Awards and close *J Tsaltas, J Abbott*

A modern operating room featuring a central surgical table, two large overhead surgical lamps, and two monitors displaying laparoscopic views. A central console holds various medical devices. The Stryker logo is visible in the top right corner.

stryker®

*i*Suite

Visualise Tomorrow, Today

Experience the **stryker®** difference

The information presented in this advertisement is intended to demonstrate the breadth of Stryker product offerings. Always refer to the package insert, product label and/or user instructions before using any Stryker product. Products may not be available in all markets. Product availability is subject to the regulatory or medical practices that govern individual markets. Please contact Stryker if you have any questions about the availability of Stryker products in your area. Products referenced with ™ designation are trademarks of Stryker. Products referenced with © designation are registered trademarks of Stryker. Copyright © 2013 Stryker Printed in Australia

Stryker Australia 8 Herbert St, St Leonards NSW 2065 T: 61 2 9467 1000 F: 61 2 9467 1010
Stryker New Zealand 515 Mt Wellington Highway, Mt Wellington Auckland T: 64 9 573 1890 F: 64 9 573 1891

www.stryker.com

Program Abstracts - Thursday 27 March 2014

SESSION 1 / 0830-0850

Is Natural Orifice Transluminal Endoscopic Surgery (NOTES) to the patient's advantage?

Ritossa M

Natural Orifice Transluminal Endoscopic Surgery (NOTES) is the term used to describe the intentional perforation of a lumen or "Natural Orifice" to access the peritoneal or other body cavity. First described in the late 1990's and initially limited to experimental models, there are now limited publications on human cases. The initial approach was transgastric, but more recently NOTES has been performed through several other orifices, including transcolonic, transvaginal, and transurethral/transcystic approaches. The interest in NOTES has led to the development of at least 2 major groups to study, review and guide clinicians. These include EURO NOTES (Europe) and NOSCAR (USA).

The potential uses of NOTES are limitless, from specimen retrieval at traditional laparoscopic surgery to procedures where the total operation is performed through the natural orifice. Operations performed to date include pancreatectomy, splenectomy, nephrectomy, oophorectomy and hysterectomy. Recent developments including, single port laparoscopy, articulating instrumentation and robotic surgery have made NOTES a realistic option for most intra-abdominal procedures. Operations performed to date include pancreatectomy, splenectomy, nephrectomy, oophorectomy and hysterectomy.

Potential advantages on NOTES include reduced post-operative pain, shortened recovery times, and improved cosmesis (lack of surgical incision scars). Apart from the obvious advantage of no visible scarring, the advantages and risks of NOTES are poorly documented. This presentation will review the available literature on NOTES focusing on the evidence to support improved patient outcome.

AUTHOR AFFILIATION: Dr Martin Ritossa MBBS, FRANZCOG; Head of Gynaecology, Northern Adelaide Health Service, South Australia, Australia.

SESSION 1 / 0850-0910

Power and the Passion - harnessing energy for minimally invasive surgery

Lyons S

The first surgical energy source was monopolar electrosurgery. With time, concern about the risk of stray-current injuries with monopolar electrosurgery (from capacitive coupling, insulation failure and direct coupling) led to the development of bipolar electrosurgery. More recently, advanced bipolar devices and ultrasonic devices

have been developed to increase the efficiency of vessel sealing. These technologies are also purported to decrease the danger from lateral thermal spread that can occur with all laparoscopic energy sources.

Unfortunately, none of the modern surgical energy sources can provide the range of tissue effects available with monopolar electrosurgery. For this reason, monopolar electrosurgery remains popular for minimally invasive surgery despite the specter of stray-current injuries. Indeed, many surgeons may be falsely reassured that modern minimally invasive surgical equipment, and new surgical modalities (e.g., single-incision and robotic-assisted laparoscopy), decrease the risk of inadvertent thermal injuries from surgical energy sources. In fact, many modern advances in minimally surgical equipment and modalities may increase the risk of patient injury from surgical energy sources.

In particular, this talk will address the following points:

1. Capacitive coupling has the potential to complicate any surgery utilizing monopolar electrosurgery.
2. Capacitive coupling can occur with plastic laparoscopic ports.
3. Capacitive coupling can occur with single-use instruments.
4. Insulation failure generally develops as a result of capacitive coupling; both may give rise to direct coupling.
5. Capacitive coupling, insulation failure and direct coupling may all result in life threatening stray-current injuries.
6. The risk of stray-current injuries is probably increased with single incision and robotic-assisted laparoscopy due to the instrument tip angulation and crossing over of instruments in close proximity.
7. Measures can be implemented to decrease or even eliminate stray current injuries from monopolar electrosurgery.
8. Advanced bipolar and ultrasonic energy sources do not eliminate lateral spread injuries.

Patient deaths due to stray current bowel injury have recently been reported at each of conventional laparoscopy, single port laparoscopy and robotic laparoscopy. We should not be surprised that stray-current injuries occur during monopolar electrosurgery, as the physical principles that dictate the current's behavior are well established. What is surprising is that available safeguards to make monopolar stray-current injury a thing of the past have generally not been embraced in an age of great technological advances for minimally invasive surgery.

Program Abstracts - Thursday 27 March 2014

REFERENCES:

1. Law, K.S. & Lyons, S.D. (2013) Comparative studies of energy sources in gynaecological laparoscopy. *J. Minim. Invasive Gynecol.* 20, 308-31
2. Lyons, S.D. & Law, K.S. (2013) Laparoscopic vessel sealing technologies. *J. Minim. Invasive Gynecol.* 20, 301-7

AUTHOR AFFILIATION: Dr Stephen Lyons; The Mater Clinic, North Sydney, New South Wales, Australia.

SESSION 1 / 0910-0930

Technological challenges in small places – intrauterine transformation

Won H

For the past few years, there has been several new developments in operative hysteroscopy to change therapeutic procedures for the treatment of benign uterine conditions. Different technologies for operative hysteroscopic procedures are evaluated along with their safety and performance.

AUTHOR AFFILIATION: Dr Haryun Won; Royal Hospital for Women, Randwick, New South Wales, Australia.

SESSION 2 / 1120-1135

Success and failure in the gynaecological market place

Abbott J

Defining success in a medical marketplace will usually require a combination of factors. These include scientific validation of a procedure, a device or a drug; economic factors in production or health-systems savings; clinical uptake in a defined area and marketing strategies, that may be specific to locality pending legal restrictions such as direct marketing. For gynaecology, success may be considered for the uptake of laparoscopic hysterectomy, that has increased its market share to 33% of all modes of hysterectomy over a 20 year interval. Compare this to the 'failure' of vaginal meshes, which have many advantages, however with marketing and widespread utilization, scientific evidence demonstrated a number of clinical complications such as erosion and pain. These successes and failures are not limited to gynaecology, with medications such as tegaserod and rofecoxib being trialled, having clinical success, being marketed and post-market research indicating substantial risk including cardiovascular effects from both drugs including myocardial infarction and CVA leading to the removal or limitations of the medications in the market.

For minimally invasive gynaecology, suburethral slings may be considered a substantial success, with good scientific data, long-term outcomes, good economic modeling and replacement of a procedure that was formally successful. Endometrial ablation offers a sound scientific evidence base, however fierce competition within the marketplace has seen the discontinuance of devices such as Microwave ablation and Vestablate – for economic reasons. The emergence of Mirena as one of the most successful medical devices in gynaecology meets all of the requirements for success and its use for many conditions is a key feature of its uptake. Hysteroscopic sterilization devices have a limited role in the marketplace, with Essure still available, although its more expensive competitor Adiana no longer available. Outpatient procedures or 'office' procedures have a regional variation with high uptake in the UK and USA but very poor uptake in Australia.

There is no single factor that determines success or failure in the gynaecological marketplace and it is a combination of factors that will ultimately lead to a rise or fall. However, it is essential that scientific validation be present, that there be a need for the device, procedure or medication and that economic factors are favourable for both the emergence and longevity of any medical intervention.

AUTHOR AFFILIATIONS: Assoc. Prof. Jason Abbott; University of New South Wales, Kensington, New South Wales, Australia. Royal Hospital for Women, Randwick, New South Wales, Australia.

SESSION 2 / 1135-1150

Costing technology and patient outcomes – making sense of the dollars

De Abreu Lourenço R

New drugs and medical procedures are often advocated for use on the basis of being cost-effective. What is really meant by the term "cost-effectiveness", and how is it determined? While understanding costs and the resource implications of new drugs, devices and procedures is critical, so too is understanding their outcomes and how they are measured. For example, outcomes may be expressed in a manner that is meaningful but context specific, such as pregnancy free years for new contraceptives, or a reduction in length of stay associated with a new surgical method. More general measures, such as the quality adjusted life year (QALY), potentially allow comparisons not only between treatments but across indications.

Such analyses of cost and outcomes should always be comparative, with their scope affected by the perspective adopted (e.g. the hospital, the State government, Commonwealth, or society). This session provides

Program Abstracts - Thursday 27 March 2014

an overview of these principles and the methods of applying health economic analysis to assess the impact of introducing new technologies. Particular attention is paid to examples from within the discipline of gynaecology, with a focus on issues arising for new and emerging technologies.

AUTHOR AFFILIATION: Mr Richard De Abreu Lourenço, MEd(Hons); Health Economist, Research Fellow, Centre for Health Economics Research and Evaluation, University of Technology, Sydney, New South Wales, Australia.

SESSION 2 - KEYNOTE LECTURE / 1200-1230

Intrauterine pathology: the evidence for diagnosis and management

Lieng M

Intrauterine pathology may cause symptoms such as abnormal uterine bleeding and have a negative impact on fertility and pregnancy outcomes.

In this presentation, clinical implications and evidence for diagnosis and management of local intrauterine pathology such as endometrial polyps, submucous fibroids, uterine septum and intrauterine adhesions will be described. Furthermore, treatment options and indications for treatment will be discussed. Finally, the implication of intrauterine pathology on fertility and pregnancy outcomes will be emphasised.

AUTHOR AFFILIATION: Assoc. Prof. Marit Lieng; Department of Gynecology, Oslo University Hospital and University of Oslo, Oslo, Norway.

SESSION 4 / 1530-1545

Becoming accredited in robot-assisted surgery – AGES and the College

Tsaltas J

OUTLINE: Robot-assisted laparoscopic surgery in Australia is performed by only a number of select advanced laparoscopic surgeons. The only robot currently available is the da Vinci surgical system, produced by Intuitive. Da Vinci surgical have developed a pathway to credential surgeons in robotic-assisted surgery but this does not override any local hospital credentialing. Having said this da Vinci Surgical's program usually aligns fairly closely with Hospitals who offer Robotic surgery. To date there has been little input from overriding bodies such as RANZCOG and the current position statement from RANZCOG on the use of the robot is fairly limited in its guidance for the gynaecological endoscopy community.

It is imperative that meetings such as this AGES meeting are convened to independently evaluate and discuss the

issues that surround this evolving area of Gynaecological Laparoscopic Practice.

The question is whether the Robot is necessary or appropriate for benign gynaecological surgery or will its usage be limited to gynaecological oncology.

REFERENCES:

1. RANZCOG Position statement on robotic assisted surgery G- Gyn 29. <http://www.ranzcog.edu.au/college-statements-guidelines.html>. Current Nov2013
2. AAGL. AAGL Position Statement: Robotic-Assisted Laparoscopic Surgery in Benign Gynecology. The Journal of Minimally Invasive Gynaecology. 2012
3. The American Congress of Obstetricians and Gynecologists (ACOG). Statement on Robotic Surgery by ACOG President James T. Breeden MD. 2013. Accessed from: http://www.acog.org/About_ACOG/News_Room/News_Releases/2013/Statement_on_Robotic_Surgery

AUTHOR AFFILIATIONS: Dr Jim Tsaltas; Head of Gynaecological Endoscopy Unit, Monash Medical Centre & Southern Health, Senior Infertility & IVF Specialist at Melbourne IVF, Melbourne, Victoria, Australia.

SESSION 4 / 1545-1600

Mini-laparoscopy, LESS, robotic single site and the next frontier in minimally invasive surgery

Escobar P

Minimally invasive surgery is one of the newest and most exciting areas of development in procedural medicine. This field shows tremendous potential to increase therapeutic benefit while minimizing some of the painful or dangerous side effects of surgical interventions. Minimally invasive surgery has strong historic ties to the field of gynecology and has come a long way as technology and techniques have improved.

This has increasingly allowed the application of laparoscopy to more complex procedures and the treatment of gynecologic malignancies. Three laparoscopic approaches, traditional laparoscopy, robotic assisted laparoscopy and laparoendoscopic single-site surgery are reviewed here. We discuss the basic approaches to these three laparoscopic techniques, and then review their applications in gynecology. We also touch on the evidence behind outcomes associated with their use.

REFERENCES:

1. Jernigan AM1, Auer M, Fader AN, Escobar PF. Minimally invasive surgery in gynecologic oncology:

Program Abstracts - Thursday 27 March 2014

a review of modalities and the literature. Womens Health (Lond Engl). 2012 May;8(3):239-50. doi: 10.2217/whe.12.13

- Levinson KL, Auer M, Escobar PF. Evolving technologies in robotic surgery for minimally invasive treatment of gynecologic cancers. Expert Rev Med Devices. 2013 Sep;10(5):603-10. doi: 10.1586/17434440.2013.827509 PMID: 24053253

AUTHOR AFFILIATIONS: Pedro F Escobar, MD, Director of Gynecologic Oncology; Instituto Gyneco-Oncológico, Hospital HIMA-Oncologico. Clinical Associate Professor of Surgery, Cleveland Clinic Lerner College of Medicine.

SESSION 4 / 1600-1615

This little piggy went wee, wee, wee, all the way home – a urological robotic story

Vass J

Robotics has revolutionized the practice of Urological surgery over the last decade. Its potential advantages in the male pelvis are ideally suited to radical prostatectomy.

At present over 80% of radical prostatectomies in the United States are done robotically up from less than 10% in 2004 and its use in other Urological procedures is increasing.

Robotic surgery is now an established part of Urological surgery but its introduction was controversial with an exponential rise in its use despite limited training opportunities.

Today robotics is an integral part of urological practice. Cystectomy and partial nephrectomy are increasingly being performed robotically. The problem of training and credentialing in Urology and the advantages and disadvantages to the surgeon and patient are discussed.

AUTHOR AFFILIATIONS: Dr Justin Vass; Royal North Shore Hospital & North Shore Private Hospital, St Leonards, New South Wales, Australia. Macquarie University Hospital Macquarie Park, New South Wales, Australia.

Applied Medical



MAJOR
SPONSOR
OF ALL 3
AGES
CONFERENCES
IN 2014

As a new generation medical device company, Applied Medical is proud to provide innovative surgical products that improve patient outcomes and enable the advancement of minimally invasive surgery.

Our dedication to understanding and satisfying our customers' needs has made Applied a leading provider of breakthrough technologies and clinical advancements for Minimally Invasive Surgery, including the Alexis® wound protectors/retractors and GelPOINT® advanced access platforms.

Applied is also committed to helping surgeons remain at the forefront of the latest techniques in Minimally Invasive Surgery. Our Master Class Workshops, SimseI® laparoscopic trainer and high-fidelity simulation platform allow surgeons to enhance their skill sets and attain hands-on experience.

To learn more, please visit www.appliedmedical.com or call 1800 666 272



Program Abstracts - Friday 28 March 2014

SESSION 5

Robot-assisted hysterectomy and myomectomy

Qin V

Hysterectomy is the most common gynaecological surgical procedures performed. In the last decade, the introduction of robotic-assisted hysterectomy has polarised opinions within the field of minimally invasive surgery. Advantages of the robotic platform include better ergonomics, wider range of motion, three-dimensional vision and reduced learning curve, compared to that of conventional laparoscopy.

The perceived advantages of the robotic platform are not yet translated into improved outcome for patients in numerous studies so far. There are almost 300 citations about robotic-assisted surgery for benign gynaecological condition, yet only 2 were randomized controlled trial comparing conventional laparoscopy and robotic-assisted surgery. The most consistent findings so far were the higher cost and longer operating time for robotic-assisted hysterectomy. The surgical outcome and complication rate were similar between conventional laparoscopy and robotic-assisted surgery. For myomectomy, all studies to date were retrospective.

For the treatment of benign gynaecologic disease, robotic-assisted laparoscopic surgery should not replace conventional laparoscopic or vaginal procedures. With the rapid uptake of robotic surgery, more research is required to compare robotic surgery against conventional laparoscopy.

REFERENCES:

1. AAGL Position Statement: Robotic-assisted laparoscopic surgery in benign gynecology. *JMIG* 2013;20(1):2-9
2. Liu H, Lu D, Wang L et al. Robotic conventional laparoscopic surgery for benign gynaecological disease. *Cochrane Database Syst Rev.* 2012;(2):CD008978 (Class I)
3. Rosero E, Kho K, Joshi G et al. Comparison of robotic and laparoscopic hysterectomy for benign gynecologic disease. *Obstet & Gynecol.* 2013;122:778-86

AUTHOR AFFILIATIONS: Dr Victoria Qin; Gynaecology Fellow, Sydney West Advanced Pelvic Surgery Unit, Lecturer at the University of Western Sydney, New South Wales, Australia.

SESSION 5

Robot-assisted gynaecological oncology

Arnold A

There are now more than 1200 robotic surgery systems in the United States. The benefits for robotic assisted surgery, among others, include increased dexterity in complex operations, 3D visualisation and surgeon comfort. Due to these reasons, robotic assisted surgery is seen to offer many potential benefits especially in fields with challenging and complex surgery, such as Gynae-oncology. Robotic assisted surgery has been used in operations for endometrial, cervical and ovarian cancer, however evidence currently consists of only case based and prospective studies.

In Gynae-oncology, endometrial cancer has become the leading indication for robotic assisted surgery. A systematic review in 2010 of 1591 patients demonstrated robotic assisted hysterectomy to be equivalent to laparoscopic hysterectomy in terms of intra operative complications and length of hospital stay. A case series of 49 obese patients undergoing robotic assisted hysterectomy (Gehrig et al) found the robotic approach to have some advantages over conventional laparoscopic hysterectomy.

In the past five years, more than 300 robotic assisted radical hysterectomies have been performed for early stage cervical cancer. The majority of the prospective studies comparing different approaches to radical hysterectomy have found favourable outcomes from the robotic assisted approach. Benefits of robotic assisted radical hysterectomy include reduced blood loss and shorter hospitalisation with no difference in intra operative complications or survival, when compared to the open approach. Fertility sparing surgery for cervical cancer has also been successfully performed by the robotic approach. Although numbers are small, reports have demonstrated robotic assisted trachelectomy to be safe and feasible

Robotic assisted surgery is less useful in ovarian cancer, where the robot is less suitable for accessing the upper abdomen. A small case controlled study of 25 patients (Magrina et al) demonstrated the feasibility of treatment of early stage and small volume ovarian cancer by robotics. Laparotomy is still the preferred option for major debulking procedures in advanced ovarian cancer.

Although good quality evidence is still required, the advantages robotic assisted surgery offers the surgeon in terms of comfort and dexterity means usage will undoubtedly continue to grow. As technology expands,

Program Abstracts - Friday 28 March 2014

robotics is also likely be implemented in other areas of obstetrics and gynaecology.

AUTHOR AFFILIATION: Dr Amy Arnold; Endo gynaecology fellow, Royal Hospital for Women, Randwick, New South Wales, Australia.

SESSION 5

Robot-assisted pelvic floor surgery

Wong C

OBJECTIVE: to present the current evidence of the feasibility, safety and cost-effectiveness of robotic surgery in pelvic floor repair surgery.

In my presentation, I will give a brief review of the history of robotic surgery and a description of the technique. Then I will go through the current evidence of feasibility, safety, long term clinical outcome and cost-effectiveness of robotic assisted sacrocolpopexy. The advantage and disadvantage of robotic surgery compared with open or conventional laparoscopic technique in sacrocolpopexy will also be explored. The learning curve associated with robotic surgery and its impact on laparoscopic skills will be discussed.

CONCLUSION: Current evidence demonstrated feasibility and safety of robotic approach for sacrocolpopexy. However, it resulted in longer operating time, increased pain and cost compared with the conventional laparoscopic approach. Robotic surgery improved surgical performance and learning compared with conventional laparoscopy.

REFERENCES:

1. Schreuder H, Verheijen R Robotic Surgery. BJOG 2009; 116:198-213
2. Siddiqui NY et al Symptomatic and anatomic 1-year outcome after robotic surgery and abdominal sacrocolpopexy. Am J Obstet Gynaecol 2012; 206:435e1-5
3. Paraiso M et al Laparoscopic Compared with Robotic Sacrocolpopexy for Vaginal Prolapse. Obstet Gynaecol 2011; 118:1005-13

AUTHOR AFFILIATIONS: Dr Clare Wong MBBS MM(RHHG) MRANZCOG; laparoscopy fellow, Sydney West Advance Pelvic Surgery Unit, Western Sydney Local Health District, New South Wales, Australia.

SESSION 6 / 1115-1130

One layer or two?

Lieng M

In this presentation, complications following previous cesarean section such as uterine rupture and uterine dehiscence will be discussed. Any evidence of an eventual impact of surgical closure techniques during cesarean section on the occurrence of uterine rupture and dehiscence will be discussed.

Finally, clinical cases of women suffering from uterine dehiscence after previous cesarean section including clinical consequences, diagnostics approaches and surgical repair of the dehiscence will be presented.

AUTHOR AFFILIATIONS: Marit Lieng; Department of Gynecology, Oslo University Hospital and University of Oslo, Oslo, Norway.

SESSION 6 – KEYNOTE LECTURE / 1200-1230

The retroperitoneum: not only for the oncologist

Escobar P

Knowledge of the surgical anatomy of the retroperitoneum is crucial for the gynecologic surgeon. The retroperitoneum can be approached and explored by several routes, including the transperitoneal route and the extraperitoneal route. Safe and reliable primary retroperitoneal access can be performed via minimally invasive surgery. This talk summarizes key aspects of surgical anatomy and techniques for the gynecologic surgeon.

AUTHOR AFFILIATIONS: Pedro F Escobar, MD, Director of Gynecologic Oncology; Instituto Gyneco-Oncológico, Hospital HIMA-Oncológico. Clinical Associate Professor of Surgery, Cleveland Clinic Lerner College of Medicine.

THE PERPETUAL DAN O'CONNOR LECTURE / 1530-1600

How technology has changed the world of fertility

Jansen RPS

Members of AGES will be familiar with the technological advances in endoscopy and microsurgery some decades ago that made accurate diagnosis of infertility possible and which led in some cases to substantial improvements in its surgical management. Likewise, the development during the last century of modern contraception to

Program Abstracts - Friday 28 March 2014

reversibly limit fertility is common knowledge. The colossal advance of the last 20 years that has changed forever the responsible and precise improvement of the probability of conceiving children free from genetically determined disability lies in the rise and rise of in vitro fertilization – to the point, now, that IVF results (measured as clinically normal, singleton, term births) are poised to surpass those of conceiving naturally, even in the most normal of circumstances.

After mammalian eggs were first fertilized in vitro c.1965, the next 20 years of IVF development were slow. From 1985, however, a series of major technological improvements (over those that, from 1978 onwards, saw the world's first IVF babies born) have constituted a technological, clinical and sociological explosion that today puts society at the point where, especially when nature fails, either quantitatively (defined as a perceived unreasonable time to conception) or qualitatively (a worrisome risk of genetically determined childhood or adult morbidity), IVF not only can avoid such morbidity but can now increase the monthly chance of conception to twice or more that found in human populations naturally.

The principal technological advances, actual or imminent, behind this changed world have comprised (a) controlled ovarian stimulation; (b) ambulatory, ultrasound-based egg retrieval; (c) sperm microinjection for extreme oligospermia and azoospermia; (d) improved embryo culture to the blastocyst stage + vitrification for embryo storage, (e) preimplantation genetic testing for familial monogenic disease including generation of embryonic stem cells; (f) rapid partial embryonic genome sequencing for karyotyping and more; (g) pronuclear transfer to replace whole-egg donation for ooplasmic deficiencies; and (h) IVF lab automation to better stabilise embryo culture conditions and to reduce human error.

AUTHOR AFFILIATIONS: Robert P S Jansen, Genea, Sydney, New South Wales, Australia. Clinical Professor, University of Sydney Central Clinical School, New South Wales, Australia.

SESSION 8 / 1600-1615

Medical management of horrific haemorrhage

Manley T

OUTLINE: Horrific haemorrhage is something that all clinicians fear and thankfully few have to deal with. Planning is key and just like surgical management of bleeding, medical management must follow a well-rehearsed algorithm to efficiently deal with this time critical situation.

At risk patients must be identified and perioperative planning is essential with special regard given to optimising haemodynamics and operative techniques. Clinicians must also have a clear understanding of the most common blood components and their indications as well as local hospital policies on their use including massive transfusion protocols.

Prompt diagnosis of concealed horrific haemorrhage can be a challenge and early signs of hypovolaemic shock must be looked for in the unwell gynaecological patient. A low threshold for suspecting intra-abdominal haemorrhage, particularly in the perioperative patient, can be life-saving. Where the clinical diagnosis of concealed bleeding is not clear, diagnostic imaging can be sought but must not delay a definitive surgical exploration.

REFERENCES:

1. Santoso JT, Saunders BA, Grosshart K. Massive blood loss and transfusion in obstetrics and gynecology. *Obstet Gynecol Surv* 2005; 60:827
2. Oriani G, Pavesi M, Oriani A, Bollina I. Acute normovolemic hemodilution. *Transfus Apher Sci.* 2011 Dec;45(3):269-74
3. Karger, R. The cost-effectiveness of autologous transfusion alternatives: an update and reappraisal. *Transfusion Alternatives in Transfusion Medicine* 2007; 9:91
4. Spann, CO. Water, electrolyte, and acid-base metabolism. *TeLinde's Operative Gynecology*, 8th ed, Rock JA, Thompson JD (Eds), Lippincott Williams & Wilkins, Philadelphia 1997

CONFLICT OF INTEREST: There is no known conflict of interest.

AUTHOR AFFILIATION: Dr Tom Manley; Gynaecological Endoscopy Unit, Monash Health, Melbourne, Victoria, Australia.

SESSION 8 / 1615-1630

Critical management of the shocked patient

Downs C

When we think about the "shocked" patient, an image of established uncontrolled bleeding and hypovolaemic shock usually comes to mind. This topic will be covered by the previous speaker in his talk "Medical Management of horrific haemorrhage"

There are several forms of shock, usually divided into cardiogenic, hypovolaemic, and distributive shock incorporating sepsis, anaphylaxis and adrenal

Program Abstracts - Friday 28 March 2014

insufficiency. This presentation will describe real life gynaecological cases where all forms of shock have occurred, and how the critical management proceeded.

CARDIOGENIC SHOCK

As students we learnt that cardiogenic shock occurs when the heart can't pump the amount of blood required by the body for its organs. Although intraoperative myocardial infarction may be rare in our population, cardiogenic shock is not. Bradycardia commonly occurs with dilatation of the cervix and can be largely prevented with a properly performed cervical block. This is an important skill to teach the registrars properly. Bradycardia and asystole can also occur at the time of gas insufflation to the peritoneal space. Patients who have had childhood congenital cardiac surgery are more commonly reaching reproductive age making arrhythmia and pacemaker management and an understanding of the underlying anatomy critical.

Rarer events causing pressure on the heart include CO₂ pneumothorax due to congenital or iatrogenic communication between the peritoneal space and the thoracic space. A case will be presented where an anti-adhesion fluid left in the peritoneal space caused delayed cardiogenic shock and a "white-out" of one lung. Another case of cardiogenic shock after gynaecological laparoscopy will be presented for you to solve.

HYPOVOLAEMIC SHOCK

The management of horrific haemorrhage has been presented, however I would like to comment briefly on the events that precede this diabolical situation and how communication between surgeon and anaesthetist are so critical in the early minutes of major vascular injury. Choose your anaesthetist wisely.

DISTRIBUTIVE SHOCK

Although we try to avoid bringing acutely septic patients to the operating room, occasionally it happens. Septic patients are often dependent on that last bit of endogenous adrenaline running through their system and even a small amount of sedation can create a critical situation.

Anaphylactic shock is seen in 1 in 6000 anaesthetics, most often the allergen is the muscle relaxant or antibiotic, and most anaesthetists have seen at least one. Despite this, anaphylaxis is commonly managed very badly as doctors do not appreciate the huge fluid shifts and intravascular depletion that occurs in the early minutes. Additionally, large doses of adrenaline have traditionally been given, often causing arrhythmias and making the situation worse. In 2013 the Anaesthetic allergy group launched ANZAAG.com¹, this website has a series of resources focusing on the use of low dose adrenaline for anaphylaxis in the presence of cardiac

output and these will be presented along with a case of anaphylaxis during laparoscopy from the 1990s, when I used to use muscle relaxants for laparoscopic anaesthesia.

Adrenal insufficiency is a rare cause of post-operative shock, corticosteroid supplementation is not recommended unless a patient takes more than 10mg of prednisone per day², or has Addison's disease. The use of intraoperative dexamethasone as an antiemetic during laparoscopy also reduces this risk in our case mix.

REFERENCES AND RESOURCES:

1. <http://www.anzaag.com/>
2. Clinical guideline for Perioperative Steroid Replacement, Royal Cornwall Hospital, NHS

AUTHOR AFFILIATIONS: Dr Catherine Downs MBBS FANZCA; VMO Anaesthetist, Department of Cardiothoracic Anaesthesia, Prince of Wales Hospital, Randwick, New South Wales, Australia. VMO Anaesthetist, Department of Anaesthesia, Royal Hospital for Women, Randwick, New South Wales, Australia.

Program Abstracts - Saturday 29 March 2014

SESSION 9 / 0830-0845

Single site surgery entry devices

Najjar H, Manley T

OUTLINE: Minimally invasive surgery has significant benefits for patient's post operative recovery and reduced port surgery is and should be a goal for all operative gynaecologists as we bring tomorrow's theatre today. Significant advances in the field of laparoscopic surgery in recent years have been dominated by robotic assisted surgery. Single site surgery has taken somewhat of a back seat due to the inherent issues with narrow operating field and reduced manipulation angle, which cause a steep technical learning curve. This type of advanced laparoscopic surgery is not in the scope of general laparoscopic training in gynaecology and therefore few operative gynaecologists have the opportunity to master this technique. With the help of newer single site entry devices this surgery becomes more ergonomic making multiport operative gynaecological procedures now in the realm of the single site surgeon.

REFERENCES:

1. Pelosi MA, Pelosi MA 3rd. Laparoscopic hysterectomy with bilateral salpingo-oophorectomy using a single umbilical puncture. *N J Med.* 1991;88(1):721-726
2. Escobar PF, Fader AN, Paraiso MF, Kaouk JH, Falcone T. Robotic-assisted laproendoscopic single-site surgery in gynaecology: initial report and technique. *J Minim Invasive Gynaecol* 2009; 16:589-91
3. Jeon HG, Jeong W, Oh CK, et al. Initial experience with 50 laparoendoscopic single site surgeries using a homemade, single port device at a single center. *J Urol.* 2010;183(5):1866-1871

CONFLICT OF INTEREST: There is no known conflict of interest.

AUTHOR AFFILIATION: Dr Haider Najjar, Dr Tom Manley; Gynaecological Endoscopy Unit, Monash Health, Melbourne, Victoria, Australia.

SESSION 9 / 0845-0900

Visionary changes in surgery

Merkur H

Adequate vision is integral to the performance of advanced endoscopic surgery. Over the last 20 years 2 D vision has been the standard. 3 D vision not only is coming, it is here.

The components of all that is required to provide high quality imaging for both 2 D and 3 D imaging is complex.

The interpretation of the images produced are processed eventually in the cerebral cortex. The production of 3 D images involve binocular vision and stereopsis at the human end, and circuitry put together by the imaging trade. The latter involves improvements in telescopes, camera heads, CCD's, fibreoptic light cables, light sources, CCU's, image management systems and finally HD monitors.

Knowledge of the entire pathway for production of adequate imaging is key to troubleshooting when technical problems occur during surgery. It also helps to be able to maximise image quality for the surgeon's benefit.

The comparison between 2 D and 3 D imaging, and the difference it makes to the surgeon is still being explored, however early data show an improvement in task performance using 3 D imaging. The improved precision provided by depth perception is apparent when using 3 D apparatuses, and there are studies already to show this to be true.

The surgery of today when using 2 D imaging already allows us to perform highly complex procedures. Improvements in 3 D imaging will surely lead to even further increments in the quality and safety of our operations, with the logical end being better patient outcomes.

AUTHOR AFFILIATIONS: Assoc. Prof. Harry Merkur; Director Sydney West Advanced Pelvic Surgery Unit, Western Sydney Local Health District, New South Wales, Australia. Assoc. Prof. O&G University of Western Sydney, New South Wales, Australia. Honorary Secretary AGES.

SESSION 9 / 0900-0915

iSurgery

Ruff M

Computers have become an integral part of some operations, with the Da Vinci surgical system used in 80% of radical prostatectomies in the United States of America and having an increasing presence in gynaecology. Robotic surgery is on the rise and forms the cornerstone of this annual scientific meeting. However computers are also assisting surgery in other ways. Navigational systems allow optimisation of the alignment of knee replacements, correct placement of pedicle screws in spinal surgery and accurate location of lesions in neurosurgery via stereotactic techniques and more.

Computers also serve an important role in bringing information into and taking information out of the operating theatre. Novel systems have been developed to assist with this process. Microsoft Kinect, the motion-

Program Abstracts - Saturday 29 March 2014

sensing device for the Xbox gaming console has been adapted to allow hands free navigation of patient imaging for the surgeon who is scrubbed. Google Glass, the internet-enabled glasses with a inbuilt camera and monitor, has been used as a teaching aid, by transmitting the surgeons visual field to a lecture theatre.

More than information can be brought into the operating theatre via our computers. With telesurgery a surgeon can perform procedures remotely, with their surgical skills being transmitted across the Internet. Research into the field of remote robotic surgery was initially funded by the Defence Advanced Research Projects Agency to bring the skill of a surgeon to wounded soldiers at the front line. While successful telesurgical procedures have been carried out, it is not yet mainstream due to limitations of cost and technology, specifically reliability of high speed networks.

This talk will outline the present state and future direction of information technology in the operating theatre, with a focus on the benefits and limitations.

AUTHOR AFFILIATIONS: Dr Mark Ruff MBBS (hons), BCST; The University of Sydney, Camperdown. New South Wales, Australia. Royal North Shore Hospital, St Leonards, New South Wales, Australia.

SESSION 9 / 0915-0930

Sonographic advances that change the way surgeons view surgery

Lanzarone V

Ultrasound has a long been useful to gynaecologist. Some recent advances which have the potential to add to the sonographic repertoire will be discussed, including novel imaging modalities such as "Fly Thru" virtual hysteroscopy and "elastography". Improvements in the understanding of the operator have also meant transvaginal ultrasound can be of more value in advanced endometriosis where we believe it has the ability to replace the diagnostic laparoscopy, and in the triaging of ovarian masses where the new IOTA simple rules hold promise of an easy and accessible means of malignancy prediction.

AUTHOR AFFILIATIONS: Dr Valeria Lanzarone; Director Penrith Ultrasound for Women, VMO Nepean and Sydney Adventist Hospitals, HMO Royal Prince Alfred Hospital, New South Wales, Australia.

SESSION 9 / 0930-0945

Cool tools that we can use. Can we borrow that?

Salfinger S

The gynaecologic surgeon needs to be aware of the full range of surgical instrumentation that is available to them. Simply settling for what the scrub nurse hands you is not the ideal option. For yourself from an ergonomic point of view from a surgical efficiency aspect and also for the benefit of the patient it is important to be aware of your options. Too often, especially in stand-alone women's hospitals, we do not appreciate the range of instrumentation available. Even within a Women's hospital we can often be unaware of what our other special interest or subspecialty colleagues are using.

We will discuss a range of "Cool Tools" that you can use to help improve surgical options, as well as patient and surgeon outcomes.

AUTHOR AFFILIATIONS: Dr Stuart Salfinger MBBS, FRANZCOG, CGO. Certified Gynaecologic Oncologist, Western Australia, Gynaecologic Cancer Service - KEMH & SJOG Hospitals, Clinical Senior Lecturer, School of Women's and Infants Health - University of Western Australia, Perth, Western Australia, Australia.

SESSION 10 / 1030-1100

Cost and robotic-assisted surgery in gynaecology – a complex problem

Escobar P

Since the introduction of robotic technology, there have been significant changes to the field of gynecology. The number of minimally invasive procedures has drastically increased, with robotic procedures rising remarkably. To date several authors have published cost analyses demonstrating that robotic hysterectomy for benign and oncologic indications is more costly compared to the laparoscopic approach. Despite being more expensive than laparoscopy, other studies have found robotics to be less expensive and more effective than laparotomy. In this review, controversies surrounding cost-effectiveness studies are explored.

REFERENCE:

1. Knight J, Escobar PF. Cost and robotic surgery in gynecology. *J Obstet Gynaecol Res.* 2014 Jan;40(1):12-7. doi: 10.1111/jog.12197. Epub 2013 Oct 11.

AUTHOR AFFILIATIONS: Pedro F Escobar, MD, Director of Gynecologic Oncology; Instituto Gyneco-Oncológico, Hospital HIMA-Oncológico. Clinical Associate Professor of Surgery, Cleveland Clinic Lerner College of Medicine.

Program Abstracts - Saturday 29 March 2014

SESSION 10 / 1100-1130

Simulation stimulation – education in a technological world

Lieng M

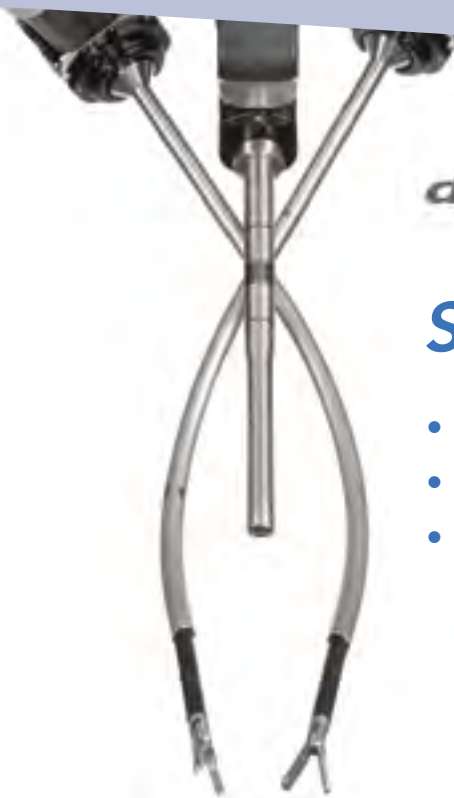
Surgical simulation has the last decade been successfully introduced into many surgical residency programs as an effort to augment training. A wide range of simulator types and levels of complexity have proven an effective teaching method for surgical and gynecological trainees.

Simulation is well suited for training in laparoscopic surgical techniques. Especially laparoscopic suturing

is recognised as one of the most difficult laparoscopic skills to master. Trainees should consequently practice laparoscopic techniques including suturing outside the operating theatre.

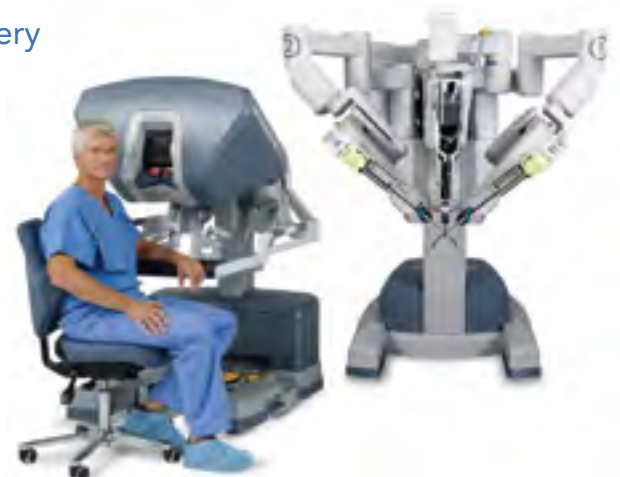In this presentation, different systems and methods for systematic laparoscopic training will be presented. Furthermore, the evidence of the effect of laparoscopic training and simulation on surgical performance will be presented and discussed.

AUTHOR AFFILIATION: Assoc. Prof. Marit Lieng; Department of Gynecology, Oslo University Hospital and University of Oslo, Oslo, Norway.



Single-Site™ Technology

- Solution to single access surgery
- Minimises pain
- Minimises scarring



Free Communications - Thursday 27 March 2014

Chairmen's Choice

SESSION 3 - CHAIRMEN'S CHOICE FREE COMMUNICATIONS / 1330-1340

The SWEC Uterine Artery Manoeuvre during TLH – bringing the target to the instrument

Tsai B, Kanade T, McKenna J, Choi S, Reyftmann L, Cario G, Rosen D, Chou D

Ligating the uterine arteries during a total laparoscopic hysterectomy is a crucial step in the surgery, and can result in intraoperative haemorrhage or ureteric injury if this step goes awry. Although total laparoscopic hysterectomies have become more widespread and the surgical techniques more mature, the quoted rates for major haemorrhage and ureteric injury are still as high as 4.8% and 1.6% respectively. Here we present a novel manoeuvre with uterine manipulation that safely isolates and presents the uterine artery in an accessible position, while displacing the ureter safely. This "SWEC Uterine Artery Manoeuvre" can be easily performed with any articulated uterine manipulator such as the Pelosi and the RUMI. In a case series of over 1000 TLHs, the rate for ureteric injury is 0% and intraoperative/post-operative haemorrhage over 500cc from the uterine arteries also 0%. We feel that this technique can help improve the efficacy and safety of TLHs for both experienced and novice laparoscopic gynaecologic surgeons. The manoeuvre will be demonstrated with verbal instructions, illustrations, intraoperative photographs, and videos.

REFERENCES:

1. Garry R et al. The eVALuate study: two parallel randomised trials, one comparing laparoscopic with abdominal hysterectomy, the other comparing laparoscopic with vaginal hysterectomy. *BMJ*. 2004 Jan 17; 328(7432):129
2. Gendy R et al. Vaginal hysterectomy versus total laparoscopic hysterectomy for benign disease: a metaanalysis of randomized controlled trials. *Am J Obstet Gynecol*. 2011 May; 204(5):388.e1-8
3. Nieboer TE et al. Surgical approach to hysterectomy for benign gynaecological disease. *Cochrane Database Syst Rev*. 2009 Jul 8;(3):CD003677
4. Trivedi P et al. Do new vessel sealing devices and harmonic ace increase ureteric injury in total laparoscopic hysterectomy? *J Gynecol Endosc Surg*. 2009 Jul; 1(2):83-8

AUTHOR AFFILIATION: B. Tsai, T. Kanade, J. McKenna, S. Choi, L. Reyftmann, G. Cario, D. Rosen, D. Chou; Sydney Women's Endosurgery Centre, Kogarah, New South Wales, Australia

SESSION 3 - CHAIRMEN'S CHOICE FREE COMMUNICATIONS / 1340-1350

Single site robotic hysterectomy: a personal journey

Chan F

Laparoscopic surgery has a clear defined role in the modern treatment of gynaecological conditions. With the development of computerised technology, complex surgical procedures can be carried out using a single incision. The new daVinci surgical system Si overcomes the problem of two dimensional in-line optics, instrument crowding, poor ergonomics and lack of triangulation found in conventional single site laparoscopy.

In this oral presentation, I will present the first 12 cases of single site robotic hysterectomy performed in Australia. Through a 2cm single incision at the umbilicus, a five lumen port is inserted. This provides access for two single-site instruments, the 8.5 mm 3DHD endoscope, a 5/10mm accessory port and insufflation adaptor. Curved 5mm instrument cannulae specifically designed to optimise triangulation toward the target anatomy and provide an unobstructed view of the surgical field. 5mm semi-rigid instruments designed with flexibility to go through curved cannulae and the rigidity to retract tissue. Single site configuration allows instruments and camera cross within the single-site port and use remote centre technology to avoid cannula collisions, arm interferences and port site movement.

The learning curve of the technique is relatively short. Patients are discharged within 24 hours after the procedure with minimal analgesic requirement and excellent cosmetic result. Further studies are needed to validate this surgical approach compares to convention surgery.

AUTHOR AFFILIATION: F. Chan; Liverpool Hospital, Liverpool, New South Wales, Australia.

SESSION 3 - CHAIRMEN'S CHOICE FREE COMMUNICATIONS / 1350-1400

Clinical audit resource: an operative data form for gynaecological endoscopic procedures at the Aga Khan University Hospital, Nairobi

Dodia RH, Obura T, Muchiri D

PURPOSE: Clinical audit determines gaps between what is being done and what should be, revising any 'lacks' in patient care processes¹, and is a vital step in quality improvement strategies including part of accreditation

Free Communications - Thursday 27 March 2014

Chairmen's Choice

processes. With an increasing number of endoscopic procedures being performed, the requirement of an audit tool was noted.

DESIGN AND METHOD: Procedures done in 2013 were retrospectively classified into groups for laparoscopy and hysteroscopy. Laparoscopy procedures were further classified and coded as diagnostic, for ectopic pregnancies, myomectomies, endometriosis, cystectomies, hysterectomies, and other (specify). Hysteroscopies were classified and coded as diagnostic, polyp resection, myoma resection, adhesiolysis, ablation, and other (specify). Complications to be checked off in the designed form included injury to bowel, ureters, bladder, major vessels, and abdominal wall vessels, uterine perforation, herniae at trocar sites, pneumoperitoneum related, gas embolism, post-op shoulder pain, vulval oedema, nerve injury, venous thrombosis/pulmonary embolism, peri-operative death, wound infections, pulmonary compromise after surgery, acute myocardial infarction after surgery, gastrointestinal haemorrhage/ulcer after surgery, urinary tract infection after surgery, and pneumonia after surgery. Electrosurgical sources (monopolar, bipolar, ultrasound) utilized and the time taken for each procedure was noted. For hysteroscopies, the distention fluid was identified and the end deficit recorded. To check on the value of such a form, all the endoscopic procedures performed in 2013 were audited and checked against the contents of the form.

OUTCOME MEASURES AND RESULTS: In 2013, 192 patients underwent laparoscopies, and 193 hysteroscopies. Of 286 patient records, 78.3% did not have complete data as per the designed form (except complications). Only 51.6% of the complete data records were by departmental faculty.

LIMITATIONS: Errors in data transcription; incomplete recording of procedure notes.

CONCLUSION AND COMMENTS: The inclusion of this data tool as a necessary and compulsory part of the operation notes for every endoscopic procedure will assist in improving procedure documentation and can provide (e.g. six monthly, or yearly) a valuable resource for audit, which would ultimately lead to higher quality of patient care once the clinical audit cycle is followed through, including feedback to groups as well as individuals.

CONFLICT OF INTEREST: None

REFERENCES:

1. Seddon M, Buchanan J; EPIQ. Quality improvement in New Zealand healthcare. Part 3: Achieving effective care through clinical audit. *N Z Med J* 2006;119(1239):U2108

AUTHOR AFFILIATION: R. H. Dodia, T. Obura, D. Muchiri; Department of Obstetrics & Gynaecology, Aga Khan University Hospital, Nairobi, Kenya.

SESSION 3 - CHAIRMEN'S CHOICE FREE COMMUNICATIONS / 1400-1410

Myosure resection of endometrial polyps under local anaesthesia in the outpatient setting: A prospective study

McIlwaine P, McElhinney B, Karthigasu K

OBJECTIVE: To evaluate patient acceptability of myosure resection of endometrial pathology in the outpatient setting in terms of patient discomfort, success rate and overall patient satisfaction

DESIGN: Prospective Study

SETTING: Outpatient hysteroscopy clinic, KEMH, WA

MATERIAL AND METHODS: From 1st September 2013 to 15th January 2014, twenty patients who had previously been diagnosed as having an endometrial polyp were agreeable to undergo myosure resection of polyp under local anaesthesia. Demographic factors and procedure details were recorded for evaluation. Patients were interviewed regarding their experience immediately following the procedure. A visual analogue score was used to assess the degree of pain experienced by patients during the procedure. Patient satisfaction rates were recorded on a scale of 1-10. Patients were asked if they would recommend the procedure to a friend or consider a repeat procedure for a recurrent polyp.

RESULTS: Patient ages ranged from 38-68 yrs (mean 49); 45% of patients were postmenopausal. Thirty per cent of patients were either nulliparous or never had a vaginal delivery. The average BMI was 33 (range 21-51.3). Mean polyp size on USS was 12mm (range 8-25mm). Three patients had coexisting submucosal fibroids which were all successfully resected. In 90% of patients (n=18); the polyps were completely resected while in 1 patient, the polyp was partially resected. Only 1 patient was unable to tolerate the procedure. Mean resection time was 20 seconds (range 6- 230s). Mean fluid deficit was 177mls.

In terms of complications, 1 patient sustained a small cervical tear which was managed conservatively and 1 patient experienced a vasovagal episode.

The mean visual analogue pain score was 38mm (range 8.3-75mm). Patient satisfaction rate was 85.5% with 90% stating that they would recommend the procedure to a friend. Fifty-five per cent of patients had had a

Free Communications - Thursday 27 March 2014

Chairmen's Choice

previous outpatient hysteroscopy, 82% of which found the Myosure to be similar or less in terms of discomfort. In the case of recurrent polyps, 75% of patients would be happy to undergo the procedure again, 15% of patients would consider it and 10% would opt for a general anaesthetic. 18 patients (90%) went home immediately following the procedure while the remaining 2 were discharged within one hour.

CONCLUSION: This study demonstrates that the myosure can be used effectively in an outpatient setting to resect endometrial pathology, with an acceptable level of patient discomfort and high patient satisfaction rate, avoiding the need for general anaesthesia.

AUTHOR AFFILIATION: P. McIlwaine, B. McElhinney, K. Karthigasu; King Edward Memorial Hospital, Subiaco, Western Australia, Australia.

SESSION 3 - CHAIRMEN'S CHOICE FREE COMMUNICATIONS / 1410-1420

The role of 'sensory substitution' or 'visual haptics' in robotic surgery

Kanade T, McKenna J, Tsai B, Choi S, Reyftmann L, Chou D, Rosen D, Cario G.

BACKGROUND: The role of haptic feedback in surgery cannot be underestimated, considering 'touch' is the earliest sense developed in the human embryology. With evolving technology in minimal invasive surgery, there is a growing concern about the lack of haptic feedback in the recently popular robotic assisted surgery. Robotic surgery, however, has several advantages over conventional endoscopic surgery, including three-dimensional vision, increased range of motion, tremor infiltration, and motion scaling. There is increasing evidence of the effectiveness and comparable surgical outcomes between laparoscopic and robotic surgeries. We review literature in search of evidence which addresses the controversy surrounding the success of robotic surgery and whether "visual haptics" can be learned through laparoscopic surgery and taken to a new level with Robotic surgery.

METHODS: A review of literature was undertaken using PubMed and MEDLINE. The following search terms were used: 'Haptic feedback' or 'haptics' or 'forced feedback' AND/OR 'Minimal invasive surgery' AND/OR 'Robotic Surgery' AND/OR 'Endoscopic surgery'.

INFERENCE: It is difficult to quantify "visual haptics" in open, laparoscopic or robotic surgery. Independent of the biomechanical advantages of the da Vinci Robot

System, 3-dimensional vision allows for significant improvement in performance times and error rates for both inexperienced residents and advanced laparoscopic surgeons. 1. Performance times are reduced by 34% using 3-dimensional imaging and error rates are reduced by 44%¹. Lack of haptic feedback in robotic surgery did not affect myomectomy in identification of fibroids or in terms of technique². Robotic assisted surgery holds great promise for improving accuracy and dexterity of a surgeon while minimalizing trauma. There are reports of direct improved accuracy when using three dimensional instead of a two dimensional vision in minimally invasive surgeries³. There is evidence that visual sensory substitution permits the surgeon to apply more consistent, precise and greater tensions to fine suture materials without breakage during robot-assisted knot tying⁴.

CONCLUSION: Lack of haptic feedback does not hold back a laparoscopic surgeon from giving the best results surgically and clinically to his patient. Literature does suggest that robotic assisted minimally invasive surgery is here to stay in presence of the surgeon's 'touch' of genius.

REFERENCES:

1. O.A J. van der Meijden, M P Schijven . The value of haptic feedback in conventional and robot-minimal invasive surgery and virtual reality training: a current review. *Surg Endosc* (2009) 23:1180-1190
2. K.J. Sasaki, A.Cholkeri-Singh, S. Sulo, C. Steller, C.E.Miller. Does the limitation of haptic feedback with robotic-assisted laparoscopy compromise our myomectomy techniques? *The Journal of Minimally Invasive Gynecology*. Volume 20, Issue 6, supplement. Pages S173-S174. November 2013
3. Badani KK, BAhndari K, Tewari A, Menon M (2005) Comparison of two-dimensional and three dimensional vision on surgical telemanipulator performance. *Surg Endosc* 15:1282-1288
4. Bethea BT, Okamura AM, Kitagawa M, Fitton TP, Cattaneo SM, Gott VL, Baumgartner WA, Yuh DD. Application of haptic feedback to robotic surgery. *Journal of Laparoendosc Adv Surg Tech A*. 2004 Jun;14(3):191-5

AUTHOR AFFILIATION: T. Kanade, J. McKenna, B. Tsai, S. Choi, L. Reyftmann, D. Chou, D. Rosen, G. Cario; Sydney Women's Endosurgery Centre, Kogarah, New South Wales, Australia.

Free Communications - Thursday 27 March 2014

Chairmen's Choice

SESSION 3 - CHAIRMEN'S CHOICE FREE COMMUNICATIONS / 1420-1430

Implication of umbilical port and endoscope size on total laparoscopic hysterectomy: A randomized control trial

Acton J, Salfinger S, Tan J

BACKGROUND: Minimizing the invasiveness of procedures drives us ever forward in the search for perfection in surgery. Mini-site laparoscopy is touted as the future of minimally invasive surgery by several articles in peer reviewed journals. Whilst mini-laparoscopy has been discussed in the literature since the 1990's, the technique has only been employed in complex surgical procedures (requiring considerable dissection) such as cholecystectomy and hysterectomy since 2009. Current literature shows that mini-laparoscopy instruments can be used without a negative impact of the surgeon but with non-significant improvement in discharge times or recovery times for the patient. There is no randomized controlled trial examining the reduction of the umbilical port from 10mm to 5mm. An audit produced by Acton and Salfinger in 2011 showed that discharge times were significantly decreased when a 5mm umbilical port were used compared with a 10mm port.

AIMS: To examine the impact of 5mm umbilical incision compared to 10mm umbilical incision on total laparoscopic hysterectomy, in particular operating time, discharge time and post-operative pain scores.

METHODS: A randomized controlled trial at St John of God Subiaco Hospital, Perth. 100 patients who were undergoing total laparoscopic hysterectomy were randomized to either 5mm (50) or 10mm (50) umbilical incision and endoscope. Randomisation was performed centrally and independently from other study procedures via a computer generated, web-based system using stratified permuted blocks of 4. Patients were blinded to their treatment. Pain scores were measured post-operatively on day 1 and day 7. A quality of life assessment was performed at 6 weeks post surgery. The primary endpoint was the difference between the two groups discharge times. Secondary outcomes were operating times, blood loss, technical difficulties, complications, change of equipment and delay secondary to equipment.

RESULTS: There was no significant difference in the two groups in BMI, parity and previous surgical procedures. Surgical time in theatre was significantly lower in the 5mm group (32.7 min) compared to the 10mm group (40.2 min) $p < 0.05$.

There was no significant difference in discharge time (hours) and discharge day in the groups (33.09 vs. 34.6 hours; 65% day 1 vs. 60% day 1, for 5 and 10mm respectively). Day 1 pain score on movement was significantly lower in the 5mm group (2.5 vs. 3.3; $p < 0.05$). Pain score day on 7 was significantly lower in the 5mm group (0.9 vs. 1.8; $p < 0.005$).

CONCLUSIONS: This is the first randomized controlled trial assessing the impact of umbilical port size on total laparoscopic hysterectomy. Previous audit data had shown that there may be a significant improvement for patients and for health care systems with improved length of stay and post-operative recovery. This randomized controlled trial was designed to examine the effect of using a 5mm incision and endoscope for total laparoscopic hysterectomy on discharge times and patient recovery. Whilst a decrease in discharge times was not seen in the 5mm group, operating time was 20% shorter and activity related pain scores were significantly lower.

AUTHOR AFFILIATIONS: J. Acton^{1,2}, S. Salfinger¹, J. Tan¹; 1.St John of God Hospital, Subiaco, Western Australia, Australia. 2.King Edward Memorial Hospital, Subiaco, Western Australia, Australia.

SESSION 3 - CHAIRMEN'S CHOICE FREE COMMUNICATIONS / 1430-1440

Obstetric outcomes following laparoscopic transabdominal cervical cerclage

Ades A, May J, Cade TJ, Umstad M

BACKGROUND: Cervical cerclage has been used as a treatment for cervical insufficiency for over 50 years. Transabdominal cerclage is indicated for cervical insufficiency not amenable to a transvaginal procedure, or following previous failed vaginal cerclage. A laparoscopic approach to abdominal cerclage offers the potential to reduce the morbidity associated with laparotomy.

AIMS: To evaluate the obstetric outcome and surgical morbidity of laparoscopic transabdominal cerclage.

METHODS: A prospective observational study of consecutive patients undergoing laparoscopic transabdominal cerclage from August 2007 to November 2013. Eligible patients had a diagnosis of cervical insufficiency based on previous obstetric history and/or a short or absent cervix. Primary outcome was neonatal survival. Secondary outcomes were delivery of an infant at ≥ 34 weeks. Surgical morbidity and complications were also evaluated.

RESULTS: Ninety-three patients underwent laparoscopic transabdominal cerclage during the study period. Five

Free Communications - Thursday 27 March 2014

Chairmen's Choice

patients underwent cerclage insertion during pregnancy; the remaining 88 patients were not pregnant at the time of surgery. Forty five pregnancies have been documented to date. Of those, 28 were evaluated for the study. The remaining patients were either early miscarriages, ectopic pregnancies or are still pregnant. The perinatal survival rate was 96.8% with a mean gestational age at delivery of 36.1 weeks. Eighty six percent of patients delivered at ≥ 34 weeks. There was one adverse intraoperative event (1.1%), with no post-operative sequelae.

CONCLUSION: Laparoscopic transabdominal cerclage is a safe and effective procedure resulting in favourable obstetric outcomes in patients with a poor obstetric history. Success rates compare favourably to the traditional laparotomy approach.

AUTHOR AFFILIATIONS: A. Ades¹, J. May², T. J. Cade¹, M. Umstad¹; 1.Department of Obstetrics and Gynaecology, Royal Women's Hospital, Parkville, Victoria, Australia. 2.Frances Perry House, Royal Women's Hospital, Parkville, Victoria, Australia.

SESSION 3 - CHAIRMEN'S CHOICE FREE COMMUNICATIONS / 1440-1450

Mesh erosion with laparoscopic mesh sacrocolpopexy with and without hysterectomy. A new non classical "Y" graft technique makes all the difference

McKenna J, Tsai B, Kanade T, Rosen D, Chou D, Cario G

Vault prolapse occurs in 1-15% of previously hysterectomised women and is best repaired with the gold standard sacrocolpopexy technique. Since the first reported laparoscopic mesh sacrocolpopexy was reported in 1991, several studies have demonstrated its clinical equivalence to open abdominal sacrocolpopexy. Its efficacy in achieving anatomical 'cure' and quality of life enhancement are well reported. Controversy still exists about the risks of mesh erosion, with rates being variously reported from 0 - 9.3%(1) There has been literature to suggest that concomitant hysterectomy dramatically increases this risk (2) and is a relative contraindication causing an increase in sacrohysteropexy and subtotal hysterectomy which may be a suboptimal approach as the cervix itself is often a major part of the problem.

In this case series of 524 laparoscopic mesh sacrocolpopexy with and without total laparoscopic hysterectomy, the mesh erosion rate was 2.29% with an overall complication rate of 2.67%. There were 301 patients (57.4%) who had concomitant hysterectomy

and 223 patients (42.6%) who had sacrocolpopexy alone. In the hysterectomy group there were 8 (2.66%) erosions and in the non-hysterectomy group there were 4 (1.79%). In almost all cases the mesh erosions occurred late after one year post-operatively, with half occurring from one to two years post-operatively and the other 50% from three to five years post-operatively. In one case the erosion occurred in the immediate post-operative period, in association with a pelvic abscess.

The Sydney Womens Endosurgery Centre (SWEC) approach to laparoscopic mesh sacrocolpopexy involves approximation of two separate mesh grafts with completely different configurations, joined not at the vault but in the presacral space before attachment to S1 below the promontory. Initial dissection in the posterior rectovaginal space is very low beneath the perineal body and very lateral to facilitate a low lateral attachment over the pubococcygeus portion of the levator fascia. This mesh portion is fashioned with two "trouser legs" cut at an angle of approximately 60 degrees, to allow for bilateral attachment, flanking the rectovaginal septum. Anteriorly the bladder base is reflected off the anterior vaginal wall and vault in the usual fashion. The two lengths of mesh are then secured to one another at least 2cm superior to the vault. It is this that may be the reason for the very low mesh erosion rate even with concomitant hysterectomy. The mesh is secured to the anterior sacral ligaments without tension.

REFERENCES:

1. Laparoscopic Sacrocolpoexy for severe vaginal vault prolapse:5year outcomes, Ross JM & Preston M. J Minim Invasive Gynecol. 2005 May-Jun;12(3):221-6
2. Effect of operative technique on mesh exposure in Laparoscopic sacrocolpopexy, Warner WB et al. Femal Pelvic Med Reconstr Surg 2012, Mar-Apr;18920:113-7

AUTHOR AFFILIATION: J. McKenna, B. Tsai, T. Kanade, Rosen, D. Chou, D. G. Cario; Sydney Women's Endosurgery Centre, Kogarah, New South Wales, Australia.

Free Communications - Thursday 27 March 2014

Chairmen's Choice

SESSION 3 - CHAIRMEN'S CHOICE FREE COMMUNICATIONS / 1450-1500

A prospective case-control study to examine for the presence of nerve fibres in the endometrium and the usefulness of endometrial biopsy as a diagnostic test for endometriosis

Ellett L, Readman E, Newman M, McIlwaine K, Villegas R, Jagasia N, Maher P

BACKGROUND: Laparoscopy and directed biopsy is currently the gold standard for making a diagnosis of endometriosis. A less invasive diagnostic test would be useful to aid gynaecologists in the treatment of patients with pelvic pain. It has been previously reported that C type unmyelinated nerve fibres can be found in the functional layer of the endometrium in women with endometriosis and not in those without endometriosis. Our aim was to see if we could reproduce these findings in our own laboratory and to assess the usefulness of nerve fibre detection as a diagnostic test for endometriosis.

METHODS: Paired endometrial curettage specimens and endometrial biopsies were obtained from 43 women undergoing laparoscopy for pelvic pain. 20 women were found to have biopsy proven endometriosis and 23 women did not have endometriosis. Immunohistochemical nerve fibre detection was performed in a blinded fashion, using anti protein gene product 9.5 (PGP 9.5)—a pan-neuronal marker.

RESULTS: PGP9.5- immunoreactive nerve fibres were present in the eutopic endometrium of some patients with endometriosis but were seen more frequently in the group without endometriosis. The presence of nerve fibres in curettages and in endometrial biopsy specimens was not effective to either diagnose or exclude endometriosis. Of the 20 women with biopsy proven endometriosis 6 were positive for nerve fibres in curettages, and 2 of the endometrial biopsy specimens were positive. Of the 23 women without endometriosis 13 were positive for nerve fibres in curettages and 6 of the endometrial biopsy specimens were positive. Hence, as a diagnostic test for endometriosis, the presence of nerve fibres in curettages has a sensitivity, specificity, positive predictive value, negative predictive value 30%, 43.5%, 31.6%, 41.7% respectively and for endometrial biopsy: 10%, 73.9%, 25%, 48.6%.

CONCLUSIONS: Our study was unable to support the use of endometrial biopsy as a non invasive test for

the diagnosis of endometriosis in women with pelvic pain. We found nerve fibres in the endometrium of patients without endometriosis and failed to demonstrate the fibres consistently in patients with biopsy proven endometriosis. Further research is needed to examine the intriguing relationship between endometrial nerve fibres, pain and endometriosis.

REFERENCES:

1. Al-Jefout M, Dezarnaulds G, Cooper M, Tokushige N, Luscombe G, Markham R, Fraser I. Diagnosis of endometriosis by detection of nerve fibres in an endometrial biopsy: a double blind study. *Hum Reprod* 2009; 24: 3019-3024
2. Tokushige N, Markham R, Russell P, Fraser IS. High density of small nerve fibres in the functional layer of the endometrium in women with endometriosis. *Hum Reprod* 2006a;21: 782-787
3. Bokor A, Kyama C.M, Vercruyse L, Fassbender A, Gevaert O, Vodolazkaia A, De Moor B, Fulop V, D'Hooghe T. Density of small diameter sensory nerve fibres in endometrium: a semi-invasive diagnostic test for minimal to mild endometriosis. *Hum Reprod* 2009;24:3025-3032

AUTHOR AFFILIATIONS: L. Ellett¹, E. Readman¹, M. Newman², K. McIlwaine¹, R. Villegas¹, N. Jagasia¹, P. Maher¹; 1. Mercy Hospital for Women, Heidelberg, Victoria, Australia. 2. Austin Hospital, Heidelberg, Victoria, Australia.

Free Communications - Friday 28 March 2014

SESSION 7 FREE COMMUNICATIONS / 1330-1339

Survey to assess current practice and factors effecting clinicians' decision to perform opportunistic bilateral salpingectomy during gynaecological surgery for benign disease

Kapurubandara S, Qin V, Anpalagan A, Merkur H, Wain G, Brand A, Hogg R

OBJECTIVE: Ovarian cancer is the most lethal gynaecologic malignancy and the vast majority is diagnosed at an advanced stage due to the lack of screening test to detect early stage-disease or pre-invasive disease. Serous Epithelial Ovarian Cancer is the most common histology representing 70% of Epithelial Ovarian Cancers (EOC)¹.

Recent epidemiological evidence supports the fallopian tube as the site of origin of pelvic serous cancers (PSC) including serous EOC². A change in surgical practice with removal of fallopian tube at the time of hysterectomy with ovarian preservation has been advocated with the claim that it can prevent pelvic serous cancers including Serous EOC in a low risk population group³.

The 2012 Royal Australian and New Zealand College of Obstetricians and Gynaecologists (RANZCOG) statement regarding the management of adnexa at the time of hysterectomy for benign gynaecological disease suggest that 'consideration to be given to bilateral salpingectomy at the time of hysterectomy with the risks and benefits be discussed with the patient on a case by case basis'.

METHODOLOGY: A survey of all Australian fellows of RANZCOG is to be performed. Information pertaining to clinician demographics, type and place of practice, years of clinical practice and the proportion of clinicians' offering prophylactic salpingectomy will be ascertained. The principle reasons contributing for and against offering prophylactic salpingectomy will be also collected.

Outcome: The findings from this study will assist in highlighting the current clinical practice in Australia when counselling patients with respect to opportunistic bilateral salpingectomy, compared to USA or European countries. The current literature with respect to pelvic serous cancer carcinogenesis, the risks and benefits of prophylactic salpingectomy will also be reviewed.

REFERENCES:

1. McCluggage WG. Morphological subtypes of Ovarian Carcinoma: a review with emphasis on new developments and pathogenesis. *Pathology* 2011;43: 420-32
2. Folkins AK, Jarboe EA, Roh MH, et al. Precursors to

pelvic serous carcinoma and their clinical implications. *Gynecol Oncol.* 2009;113: 391-396

3. Salvador S, Gilks B, Kobel M, et al. The fallopian tube: primary site of most pelvic-high grade serous carcinomas. *Int J Gynecol Cancer.* 2009;19:58-64

AUTHOR AFFILIATIONS: S. Kapurubandara¹, V. Qin², A. Anpalagan¹, H. Merkur², G. Wain¹, A. Brand¹, R. Hogg¹; 1. Westmead Hospital, Westmead, New South Wales, Australia. 2. Sydney West Advance Pelvic Surgery Unit, Western Sydney Local Health District, New South Wales, Australia.

SESSION 7 FREE COMMUNICATIONS / 1339-1348

Use of ureteric catheter (lighted and non-lighted) in challenging cases

Titiz H

Ureteral injury is a rare but important complication of gynecologic surgery with serious morbidity. Gynecologic surgery accounts for 75% of iatrogenic ureteral injuries. Incidence of ureteral injury is 1-8% during abdominal and pelvic surgery. Nearly half of them diagnosed after the operation. Use of prophylactic ureteric stent may reduce the risk of ureteric injury. It has been controversial. Literature was reviewed. Evidence and opinion against and for the use of prophylactic ureteric stents were presented.

Aim of this video is to demonstrate how ureteric catheter (lighted, non-lighted) can prevent ureteric injury at all levels (pelvic brim, ovarian and uterine vessels, pelvic side wall, vaginal cuff) in these challenging cases: Case 1:Laparoscopic Right oophorectomy for persistent ovarian complex cyst after failed oophorectomy by laparotomy. Case 2: Total laparoscopic hysterectomy for cervical- intraligamentous fibroid Case3: Total laparoscopic hysterectomy in a patient with the history of bilateral ureteric re-implantation Case 4:Total laparoscopic hysterectomy and bilateral salpingo-oophorectomy in a frozen pelvis with bilateral endometrioma.

REFERENCES:

1. Jay A et al. Protect the ureters JSLS, 2009,13:139-141
2. Kuno K et al, Prophylactic ureteral catheterization in gynecologic surgery.*Urology*,1998, 52(6):1004-8
3. Pokala et al. A randomized controlled trial comparing simultaneous intra-operative vs sequential prophylactic ureteric catheter insertion in re-operative and complicated colorectal surgery. *Int J Colorectal Dis* 2007, 22:683-687

AUTHOR AFFILIATION: H. Titiz; Evin Women's Health, Stafford, Queensland, Australia.

Free Communications - Friday 28 March 2014

SESSION 7 FREE COMMUNICATIONS / 1348-1357

Hysterectomy and endometrial hyperplasia: outcome and management, clinical experiences at SWAPS

Qin V, Merkur H

Atypical endometrial hyperplasia (AEH) is a precancerous condition. Risk factors for AEH are the same as those for endometrial cancer. With the rising epidemic of obesity in developed countries, increasing incidence of AEH and endometrial cancer are foreseeable and predictable consequences. Controversy still exists regarding whether AEH should be referred to a tertiary gynaecology service, with a reported concurrent cancer rate more than 50%. In post-menopausal women, bilateral salpingo-oophorectomy is routinely recommended for surgical treatment of AEH.

OBJECTIVE: To review the clinical experience of surgical treatment of AEH at a large laparoscopic unit.

METHODS: This study is a retrospective study of all cases of hysterectomy between 2009 to 2013, where endometrial hyperplasia was identified upon final histopathology or as the initial indication for surgery. Pre-op and post-op histopathology results were reviewed and compared. Other clinical details to evaluate included the mode of hysterectomy, the incidence of concurrent cancer and the option of conserving ovaries.

RESULTS: The overall incidence of AEH is low and laparoscopic hysterectomy is a safe surgical treatment for it. Pre-operative endometrial sampling by hysteroscopy was used to exclude any concurrent uterine carcinoma, therefore the incidence was extremely low. The option of ovarian conservation at the time of hysterectomy needs to be discussed and may be offered even in post-menopausal women. Inadvertent finding of AEH was uncommon among asymptomatic patients undergoing hysterectomy for other benign indications.

CONCLUSION: Atypical endometrial hyperplasia can be treated safely and effectively in a general gynaecology unit with proper pre-operative evaluation and planning.

REFERENCES:

1. Antonsen SL, Ulrich L, Hogdall C. Patients with atypical hyperplasia of the endometrium should be treated in oncological centres. *Gynecol Oncol* 2012;125(1):124-8
2. Creasman WT, Morrow CP, Bundy BN et al. Surgical pathologic spread patterns of endometrial cancer. A Gynecologic Oncology Group Study. *Cancer* 1987;60:2035

AUTHOR AFFILIATION: V. Qin, H. Merkur; Sydney West Advance Pelvic Surgery Unit, Western Sydney Local Health District, New South Wales, Australia.

SESSION 7 FREE COMMUNICATIONS / 1357-1406

A novel method to facilitate uterine delivery at robotic hysterectomy

Manolitsas T

Following completion of robotic hysterectomy, the uterus is usually delivered via the vagina. In cases where the vaginal capacity is inadequate, the uterine size is too great or a combination of the two, vaginal delivery may not be possible. In such cases, the surgeon then has a number of options including uterine morcellation, enlargement of the vaginal introitus by episiotomy or abdominal delivery of the specimen. Uterine morcellation is contraindicated in cases of malignancy or suspected malignancy due to the risk of dissemination of malignant cells and destruction of the anatomical structure of the specimen. Episiotomy may be helpful in cases of introital stenosis but will not be helpful if the vaginal vault and upper vagina is narrowed. Abdominal delivery will require formation of a small transverse or vertical incision and will result in increased post op pain and recovery time as well as a poorer cosmetic result. Another method, previously unreported in the literature, is to enlarge the vaginal vault by making a full thickness linear incision down the midline of the anterior vaginal wall.

Two cases of robotic hysterectomy were performed in morbidly obese, post menopausal patients. Preoperative diagnosis was grade 3 endometrial carcinoma in one patient and complex atypical hyperplasia in the other. In both cases the hysterectomy component of the surgery was completed and the uterus could not be delivered per vagina. Morcellation was contraindicated in both cases. Following circumferential colpotomy to complete the hysterectomy, the anterior vaginal edge is grasped and held under tension. The bladder is then carefully dissected from the anterior vaginal wall along the avascular plane for a distance of approximately 5cm. A full thickness linear incision is then made along the middle of the anterior vaginal wall, stopping just short of the bladder. This 5 cm anterior vaginal incision will result in a 10 cm increase in the circumference of the vaginal vault and increase the diameter of the vaginal vault by about 50%. In the two cases presented, this method facilitated successful vaginal delivery of the uterine specimens and avoided the need for an abdominal incision. A video will be presented demonstrating the technique to enlarge

Free Communications - Friday 28 March 2014

the vaginal vault to facilitate delivery of the uterine specimen.

AUTHOR AFFILIATIONS: T. Manolitsas; Monash Medical Centre, Clayton, Victoria, Australia. Cabrini Hospital, Malvern, Victoria, Australia. Epworth East Hospital, Box Hill, Victoria, Australia.

SESSION 7 FREE COMMUNICATIONS / 1406-1415

Setting the table: a practical guide to robotic docking from the SWEC experience

Tsai B, Choi S, McKenna J, Kanade T, Reyftmann L, Cario G, Rosen D, Chou D

As robot-assisted benign gynaecologic surgery gains popularity in Australia and more gynaecologic surgeons take up this technology, proper docking of the da Vinci Surgery System will become an integral part of the learning curve. Here we present some of the present literature on docking techniques and SWEC's experience, with a practical guide to streamline the docking process.

The various docking techniques: centre (traditional), side, and parallel-side will be described with their respective pros and cons. The benefits of side docking include the present of a second assistant and access to the vagina/perineum allowing instrumentation of the uterus and removal of specimen. Tips on side docking will be shared involving theatre setup, robotic arm configuration/angles, and port placement in order to minimize instrumental clashing and allow access/reach of the robotic arms to all fields of surgery. Our learning curve with docking will be shared as well.

This will be a practical guide with diagrams, photographs, and videos outlining the appropriate setup and steps for side docking with the da Vinci robot, thus offering an advantageous starting point for gynaecologic surgeons wishing to take up robotic surgery.

REFERENCES:

1. Chan ES. Side-docking technique for robot-assisted urologic pelvic surgery. *Urology*. 2013 Dec;82(6):1300-3
2. Einarsson JI et al. Side docking: an alternative docking method for gynecologic robotic surgery. *Rev Obstet Gynecol*. 2011;4(3-4):123-5
3. Iranmanesh P et al. Set-up and docking of the da Vinci surgical system: prospective analysis of initial experience. *Int J Med Robot*. 2010 Mar;6(1):57-60
4. Sendag F. Analysis of the learning curve for robotic hysterectomy for benign gynaecological disease. *Int J Med Robot*. 2013 Dec 27. [Epub ahead of print]

5. Silverman S et al. Parallel side-docking technique for gynecologic procedures utilizing the da Vinci robot. *J Robot Surg*. 2012 Sep;6(3):247-249
6. Uffort EE and Jensen JC. Side docking the robot for robotic laparoscopic radical prostatectomy. *JLS*. 2011 Apr-Jun;15(2):200-2
7. Woods DL et al. Side-docking in robotic-assisted gynaecologic cancer surgery. *Int J Med Robot*. 2011 Mar;7(1):51-4

AUTHOR AFFILIATION: B. Tsai, S. Choi, J. McKenna, T. Kanade, L. Reyftmann, G. Cario, D. Rosen, D. Chou; Sydney Women's Endosurgery Centre, Kogarah New South Wales, Australia.

SESSION 7 FREE COMMUNICATIONS / 1415-1424

Hysteroscopic resection of complete uterine septum in two cases with different presentations – 'scope of the resectoscope'

Kanade T, McKenna J, Tsai B, Choi S, Reyftmann L, Rosen D, Cario G, Chou D

This is a video presentation of two cases with complete uterine septum. The purpose of this video is to demonstrate minimal invasive technique as an effective option for treatment for patients symptomatic with Mullerian anomalies.

The first case is of a 23 year old nulligravida with pelvic discomfort. Her ultrasound showed uterus with two cavities and two cervixes. Her CT scan and sonohysterogram reports described bicornuate uterus bicollis. She underwent hysteroscopic excision of uterine septum under laparoscopic guidance. On hysteroscopy, we visualised two cervixes and a complete uterine septum and laparoscopy showed a shallow ridge at the fundus. The septum was excised carefully keeping in view the extent through laparoscopic telescope. Excision was carried out till the fundus superiorly and short of the internal os. Both her cervixes were left intact to avoid future possibilities of incompetent cervical os. Post excision the sonohysterogram shows a single uterine cavity with regular endometrium, confirming success in the procedure.

The second case is of a 37 year old lady with history of recurrent miscarriages. Her sonogram showed a complete uterine septum which gradually thinned towards the cervix. Clinical examination revealed one cervix. Patient was posted for hysteroscopy with resection of uterine septum under laparoscopic guidance. Diagnostic hysteroscopy to both horns was performed showing two

Free Communications - Friday 28 March 2014

cavities almost the similar capacities, with possibly slight dominance on Right side. Right cervical canal dilated and resectoscope was introduced and septum divided. Septum was divided all the way up to the fundus. Excision performed caudally to the level of internal os, so to avoid cervical incompetence. Post-surgery, this patient was reported to be pregnant, revealing the effectiveness of the procedure.

The average operative time for both the procedures was 45 minutes and the average approximate blood loss was 60 ml.

The combination of hysteroscopy and laparoscopy is a reliable method for the diagnosis and treatment of uterine septum. With a shorter operative time, less blood loss, a significantly increased postoperative pregnancy rate, transcervical resection of the septum is the preferred method for the treatment of uterine septum, and surgical instruments and skills were critical to the prognosis of uterine septum.

REFERENCE:

1. Hysteroscopic Transcervical Resection of Uterine Septum. Sumin Wang, MD, Xiaoyan Shi, MD, Xiangdong Hua, MD, Xiaoyan Gu, MD, Dazhen Yang, MD. *Journal of the Society of Laparoendoscopic Surgeons.* (2013)17:517-520

AUTHOR AFFILIATION: T. Kanade, J. McKenna, B. Tsai, S. Choi, L. Reyftmann, D. Rosen, G. Cario, D. Chou; Sydney Women's Endosurgery Centre, Kogarah, New South Wales, Australia.

SESSION 7 FREE COMMUNICATIONS / 1424-1433

An ultrasound based staging system as a preoperative triage tool for laparoscopic treatment of endometriosis

Menakaya UA, Reid S, Lu C, Infante F, Condous G

BACKGROUND: The World Endometriosis Society (WES) recommendation for the establishment of centers of expertise for management of higher stage endometriosis requires a reliable and accurate preoperative triaging system to facilitate referral of patients with higher stage endometriosis. Unfortunately current staging schemes are inadequate as preoperative triage tools for endometriosis.

OBJECTIVE: To correlate a preoperative ultrasound based staging system for endometriosis with the laparoscopic skills required for surgical treatment.

METHODOLOGY: A retrospective review of 200 patients who had laparoscopic surgery for endometriosis over

a 5-year period. All patients underwent a standardized preoperative transvaginal ultrasound using a 5 domain systematic approach.

Based on the ultrasonographic features, a preoperative staging system was developed that allows immediate comprehension of the severity of the disease and predicts the level of surgical difficulty expected at laparoscopy. Components of this staging system include presence of endometrioma, presence of deep infiltrating endometriotic nodules, status of the POD and presence of positive soft markers in particular ovarian mobility and visual analogue scores for pain. The stages were assigned numbers 1 – 4. Stage 4 was the most severe form of disease. All the 200 cases were reviewed and retrospectively assigned a stage.

The surgical reports of all 200 cases were also reviewed and using the guidelines recommended by the Royal Australian and New Zealand College of Obstetrics and Gynecology (RANZCOG) and the Australian Gynecology and Endoscopic Society (AGES) for performing advanced laparoscopic surgery in Australia we assigned a skill level required for performing laparoscopic surgery for each case. The laparoscopic skill levels were assigned based on the pelvic pathology described by the surgeon in the operation report. There are 6 laparoscopic skill levels described in this guideline.

The preoperative ultrasonographic stages were then compared with the laparoscopic skill level required to determine any correlation.

RESULT: The sensitivity and positive predictive value for predicting the need for skill levels 6 and skill levels 1 - 2 was 88.5% and 79% and 93.9% and 92%, respectively.

Overall, there was substantial agreement (Cohan's kappa 0.70) between our ultrasound prediction of surgery level required and the actual requirement for surgery using this staging system. The accuracy of predicting the exact level of skills required for surgery was 80.3%.

CONCLUSION: This new ultrasound based preoperative staging system correlates well with the level of skill required to perform laparoscopic surgery for endometriosis especially when there is minimal and severe disease. It may have a role in the preoperative triage of patients with higher stage disease. Large-scale multi center prospective studies will be needed to validate this staging system.

AUTHOR AFFILIATIONS: U. A. Menakaya¹, S. Reid², C. Lu¹, F. Infante¹, G. Condous¹; 1. Nepean Hospital, Penrith, New South Wales, Australia. 2. Royal Hospital for Women, Randwick, New South Wales, Australia.

Free Communications - Friday 28 March 2014

SESSION 7 FREE COMMUNICATIONS / 1433-1442

Robotic assisted laparoscopic segmental cystectomy, for deeply infiltrating endometriosis of the bladder

Manley I, Tsaltas J, Harewood L, Berkowitz E

CONFLICT OF INTEREST: There is no known conflict of interest.

OUTLINE: Definitive treatment of symptomatic endometriotic nodules infiltrating the bladder wall is full thickness segmental cystectomy. Minimally invasive surgery to remove these lesions is now the standard of care to reduce hospital stay and perioperative morbidity such as pain and blood loss. Robotic assisted laparoscopy may increase the surgical efficiency of excision and repair and therefore reduce operative time over standard laparoscopy.

Presented here are two cases of bladder endometriosis both excised with the assistance of the Da Vinci Surgical System Robot.

REFERENCES:

1. Pastor-Navarro H, Giménez-Bachs JM, Donate-Moreno MJ, et al. Update on the diagnosis and treatment of bladder endometriosis. *Int Urogynecol J Pelvic Floor Dysfunct* 2007; 18:949
2. Lousquy R, Borghese B, Chapron C. Deep bladder endometriosis: how do I...to perform a laparoscopic partial cystectomy? *Gynecol Obstet Fertil* 2010; 38:697

AUTHOR AFFILIATIONS: T. Manley¹, J. Tsaltas¹, L. Harewood², E. Berkowitz¹; 1.Monash Health, Clayton, Victoria, Australia. 2.Royal Melbourne Hospital, Parkville, Victoria, Australia.

SESSION 7 FREE COMMUNICATIONS / 1442-1451

Cervical cerclage - 100 years on, time to mainstream a laparoscopic approach?

McKenna J, Kanade T, Tsai B, Cook J, Rosen D, Chou D, Cario G

It is over one hundred years since the first vaginal cerclage was placed but it still remains a procedure somewhat cloaked in both relative obscurity and controversy. With ill-defined patient populations of presumed benefit and an array of surgical approach to effect suture placement; what is the best technique,

when is the optimal time to place it and in whom should it be used? The answers to these questions are emerging.

In terms of surgical approach, a recent Royal College guideline¹ has done little to further the cause for those surgeons pioneering a laparoscopic technique, stating that there is no evidence to support a laparoscopic approach over laparotomy. This is likely because studies demonstrating equal efficacy in terms of outcome and fewer operative complications have small numbers of patients. Even from large units, the numbers are small and randomised studies are unlikely to emerge. Nevertheless, there is a small but growing body of evidence to support it².

We would like to present a case series on over 20 patients who underwent laparoscopic cervico-isthmic suture placement using two different techniques. The majority of these cases had their suture placed as an interval procedure, with 15% undergoing suture placement in the index pregnancy. Discussion will cover demographic and obstetric historical information, method of diagnosis of cervical incompetence, timing of placement and operative technique used to include type of suture placed, position, tensioning and tips for success. Complication and live birth rate over 34 weeks will also be covered in the oral communication.

REFERENCES:

1. Royal College of Obstetricians and Gynaecologists, UK Green-top Guideline No60, May 2011, Cervical Cerclage
2. Preconceptional laparoscopic abdominal cerclage: a multicenter cohort study, Burger NB et al, *American Journal of Obstetrics and Gynaecology*, 2012 Oct;207(4):273.e1-273e.12.

AUTHOR AFFILIATION: J. McKenna, T. Kanade, B. Tsai, J. Cook, D. Rosen, D. Chou, G. Cario; Sydney Women's Endosurgery Centre, Kogarah, New South Wales, Australia.

Free Communications - Digital Communications

Thursday 27 March 2014

DIGITAL COMMUNICATIONS SESSION / 1030-1035

Surgical training in gynaecology; the past, present and future

Acton J, Salfinger S

In 2009 a Survey of Surgical Skills of RANZCOG trainees was published in the ANZJOG. This study looked at the procedures that trainees performed, how confident and competent they were at performing them throughout their training and how they felt about their surgical training. Disturbingly, the final year trainees did not feel competent to perform several operations independently. These included classical caesarean section, B-Lynch suture, abdominal hysterectomy, level 3 laparoscopy or vaginal hysterectomy and vaginal repairs. The level six trainees were also not competent or confident to deal with any surgical complications. Teaching was felt to be reasonable with obstetrics, abdominal and vaginal surgery, but poor in laparoscopic and surgical complications.

This problem is not confined to Australia. Worldwide there has been a decline in training opportunities resulting from several factors, including work-hour restrictions, increased subspecialisation and the treatment of previously surgically managed condition with interventional radiologic procedures and effective medical therapies.

There is also felt to be a large variation in the rotations and surgical experience of each individual trainee. When the rotations and surgical numbers of the second year trainees in WA were examined in 2011 experiences was vastly different. This data has not been used by the T&A committee to examine rotations and no changes have been made to the method by which rotations are allocated.

This data has been updated as this cohort has now completed their ITP training. The differences in the training numbers were again examined, as well as a short survey asking their confidence/experience with certain procedures. This data was compared with a logbook from 10 years ago, further highlighting the differences.

The solution for these issues is not simple. The college has recently released a new curriculum with some positive changes. One of these steps is to include formative and summative assessments in the procedural skills assessments. Evidence has shown that self-assessment and reflection are key components of surgical expertise¹.

RANZCOG recognizes decrease in patient availability for training but interestingly there is no provision for

improving this within the new curriculum. Overall, research shows there is a positive relationship between simulation training and learning outcomes, with growing evidence that using simulation results in participant satisfaction, self-reported increased knowledge and improved performance². There is convincing evidence for the efficacy of the use of simulators in basic laparoscopic training^{3,4,5}. The American College of Obstetrics and Gynecology has introduced simulation modules into its curriculum to address the decline in surgical exposure to its residents. The FRANZCOG curriculum could be improved by the introduction of a similar module.

In summary, despite countless discussion since the article was published in 2009 there has been little change to the surgical experience of the trainees. The college must examine if adequate surgical training can occur with the current numbers and if not must not increase these further. Training sites must examine the experience each trainee is getting more closely and tailor these rotations effectively. The possibility of a surgical stream within our training must be discussed further, as it may be the only way to provide adequate training.

REFERENCES:

1. Sadideen, H, Kneebone, R, 'Practical skills teaching in contemporary surgical education: how can educational theory be applied to promote effective learning?' The American Journal of Surgery, vol. 204, p396-401
2. Weller J, Nestal D, Marshall S, Brooks P, Conn, J. Simulation in clinical teaching and learning. Med J Aust 2012; 196 (9):594
3. McGaghie WC, Issenberg SB, Petrusa ER, Scalese RJ. A critical review of simulation-based medical education research, 2003-2009. Med Educ 2010; 44: 50-63
4. Larsen CR, Oestergaard J, Ottesen BS, Soerensen JL. The efficacy of virtual reality simulation training in laparoscopy: a systematic review of randomized trials. Acta Obstet Gynecol Scand 2012;91:1015-1028
5. Banks EH, Chundnoff S, Karmin I, Wang C, Pardanani S. Does a surgical simulator improve resident operative performance of laparoscopic tubal ligation? Am J Obstet Gynecol. 2007;197(5): 541.e1-e5

AUTHOR AFFILIATIONS: J. Acton^{1,2}, S. Salfinger¹; 1.St John of God Hospital, Subiaco, Western Australia, Australia. 2.King Edward Memorial Hospital, Subiaco, Western Australia, Australia.

Free Communications - Digital Communications

Thursday 27 March 2014

DIGITAL COMMUNICATIONS SESSION / 1035-1040

How to avoid and manage catastrophic vascular bleeding during laparoscopy

Lam A, Ford R, Almotrafi T, Mangat M, Salama Y, Ford S

BACKGROUND:

Major vessels lie in the retroperitoneal space of the abdomen and pelvis. These could be at risk of injury during laparoscopic surgery.

Patients at high risk for major vascular injury include severe endometriosis, large fibroids in the broad ligament or those occupying the pelvic cavity or expanding towards the pelvic sidewalls, entrapped ovarian cysts, or those undergoing pelvic lymphadenectomy. These vessels may also be at risk from Veress needle and trocar insertion.

With increasing complexity of cases being managed by laparoscopic and robotic surgery, surgeons performing laparoscopic surgery without planning, practice and rehearsal at management of major vascular bleeding may encounter massive haemorrhage, exsanguination and fatal outcomes.

OBJECTIVES:

In this presentation, we present and discuss the standard protocol for management of unexpected major haemorrhage during laparoscopic surgery.

Specific discussion will be on equipment, anesthetic and staff considerations.

A selection of clinical cases performed by surgeons at CARE will be presented to illustrate the different techniques and methods for controlling major haemorrhage.

KEY POINTS:

- Surgeons should carefully consider the level of difficulty and the risk of major haemorrhage when selecting cases for laparoscopic surgery
- Thorough preoperative assessment should include history, clinical examination, imaging and inter-disciplinary consultation
- Appropriate equipment, experienced theatre staff, support of anaesthetic and vascular colleagues are prerequisites for safe and efficient response to major vascular bleeding during laparoscopic surgery.

AUTHOR AFFILIATION: A. Lam, R. Ford, T. Almotrafi, M. Mangat, Y. Salama, S. Ford; Centre for Advanced Reproductive Endosurgery (CARE), St Leonards, New South Wales, Australia.

DIGITAL COMMUNICATIONS SESSION / 1040-1045

Strategies and methods to overcome difficult laparoscopic tissue retrieval

Lam A, Khong SY, Ford R, Morris A, Almotrafi T, Mangat M

BACKGROUND: Laparoscopic retrieval of tissue specimens can be challenging via small operative ports, resulting in longer operative and anaesthetic time.

Concerns exist regarding specimen rupture or spillage during laparoscopic dissection and specimen removal.

OBJECTIVES: In this presentation, we discuss the factors behind the selection of strategies and the choice of methods to maximize safety and efficiency for specimen retrieval at laparoscopic surgery.

A selection of clinical cases performed by surgeons at CARE will be presented to illustrate the different techniques including:

- Direct retrieval of excised specimen
- Decompression of cysts
- Tissue morcellation performed manually or with a electrical morcellator.
- Specimen retrieval bags
- Minilaparotomy
- Colpotomy with laparoscopic guided removal of specimen

KEY POINTS:

- Surgeons should carefully consider the factors which determine strategies and methods of tissue extraction and removal, namely pathology, size and consistency.
- Thorough preoperative assessment should include history, clinical examination, imaging modalities and tumour markers.
- Surgeon should have specialized training and experience in patient selection and understand the benefits and limitations of laparoscopic surgery.
- Appropriate equipment and experienced theatre staff are prerequisites for safe and efficient laparoscopic tissue excision, extraction and removal.

AUTHOR AFFILIATION: A. Lam, S. Y. Khong, R. Ford, A. Morris, T. Almotrafi, M. Mangat; Centre for Advanced Reproductive Endosurgery (CARE), St Leonards, New South Wales, Australia.

Free Communications - Digital Communications

Thursday 27 March 2014

DIGITAL COMMUNICATIONS SESSION / 1045-1050

Appendicitis and pregnancy

Berlund P, Jeyarajan E, Pulhalla H, Fleming T

BACKGROUND: Acute appendicitis is the most common pathological indication for abdominal surgery in the pregnant patient. Appendicitis has the potential for adverse outcomes for both the mother and fetus. The laparoscopic approach has become the standard treatment of appendicitis for the non-pregnant patient and has well established benefits of reduced post-operative pain and shorter hospital admission time. While its use in pregnancy has increased dramatically, controversy still remains about whether this technique poses higher risk to the fetus than the traditional management via laparotomy.

METHODS: A retrospective cohort analysis of pregnant patients admitted for the diagnosis and management of presumed appendicitis was undertaken between July 2011 and December 2013. The histology of the operative specimens was reviewed and obstetric outcomes analysed for these patients.

RESULTS: Our data demonstrated a benign histology rate at 37%. Negative histology conferred a high pregnancy success rate, with all patients found to have an uncomplicated course following their appendicectomy if the histology was benign. Of the patients with histologically confirmed appendicitis whose pregnancy outcomes were known, there was a 17% adverse outcome rate (2 of 12 patients) where the outcome was likely linked to the disease.

CONCLUSIONS: The high rate of normal appendiceal histology is supported by literature reflecting on the difficulties in diagnosing appendicitis in both the general and pregnant population. While the pregnancy for majority of patients was essentially unaffected by either the laparoscopy nor the appendicitis, it is clear that intra-abdominal infection is a risk factor for adverse pregnancy outcome via miscarriage or pre-term labour. Two large systematic reviews have suggested worse fetal outcome with the laparoscopic technique compared with open technique. Due to the small number of open procedures now performed we are unable to replicate this finding. One large retrospective review found an association between negative appendix histology and fetal loss or early delivery, this data has not been supported in our trial.

AUTHOR AFFILIATIONS: P. Berlund¹, E. Jeyarajan², H. Pulhalla², T. Fleming¹; 1.Gold Coast University Hospital Department of Minimally Invasive Gynaecology, Southport, Queensland, Australia. 2.Gold Coast University Hospital Department of General Surgery, Southport, Queensland, Australia.

Free Communications - Digital Communications

Thursday 27 March 2014

DIGITAL COMMUNICATIONS SESSION / 1230-1235

Laparoscopic E/O ultralow rectal endometriosis

Lam A, Almotrafi T

28 years single lady presents: pain in the rectum/buttock, radiates to the right buttock and leg.

Starts day 1 of the period, lasts for 2 days.

Debilitating pain, affect her work. -Frequent bowel movements (2-3) times day 1 of menses, urge to defecate.

She was on OCP for 5 years.

EXAMINATION: Large posterior fornix (rectovaginal nodule 3X3X3) with scarring extending toward the sacrum and lateral toward the pelvic sidewall.

OPERATIVE FINDINGS:

Uterovesical space- multiple deep endometriotic implants up to 2 cm.

Bladder- 3x3x3 cm nodule at the bladder dome, left of the midline.

POD obliterated, rectum puckered toward the right uterosacral junction.

Rectovaginal septum-huge 5x54 cm nodule infiltrate into the posterior fornix, Uterosacral junction, right pararectal, right uterosacral, under the right uterine vessels, firmly onto right levator ani fascia.

AUTHOR AFFILIATION: A. Lam, T. Almotrafi; Centre for Advanced Reproductive Endosurgery (CARE), St Leonards, New South Wales, Australia.

DIGITAL COMMUNICATIONS SESSION / 1235-1240

A novel approach to robotic sacral hysteropexy

Al-Salihi S, Carey M

INTRODUCTION: Prolapse of the uterus has traditionally been managed by vaginal hysterectomy and with some form of vaginal surgery to re-support the vaginal apex (e.g. sacrospinous ligament fixation, uterosacral ligament suspension). Up to 44% of women undergoing prolapse surgery have a concomitant hysterectomy¹. However, as a result of changing trends in patient preferences there is an increasing need for uterus preservation at the time of surgery for pelvic organ prolapse. Sacral hysteropexy (suspension of the uterus from the sacral promontory using mesh) is one surgical option for the management

of prolapse that conserves the uterus. In our experience, current methods of sacral hysteropexy that focus on mesh attachment to the posterior cervix typically result in marked anteversion of the uterus resulting in the sensation of recurrent prolapse for some patients. This often remains the case even when mesh straps are placed onto the anterior cervix and/or upper anterior vagina².

This video presentation describes a new approach to robotic sacral hysteropexy using a U-shaped mesh. After attachment of the mesh onto the anterior cervix and upper anterior vaginal wall, the mesh straps are drawn through avascular windows in the broad ligament lateral to the uterus on both sides and attached to the anterior longitudinal ligament on the sacral promontory. The U-shaped mesh acts like a sling in suspending the uterus and upper anterior vagina from the sacral promontory. This results in the uterus obtaining a neutral position and obviates the risk of mesh detaching from the uterus. This neutral position of the uterus is likely to reduce the risk of patients experiencing the sensation of recurrent uterine and upper anterior vaginal wall prolapse.

METHODS: A 51 year woman presented with recurrent vaginal prolapse (stage II: Aa 0; Ba 0; C 0; D -2; GH 4.5; PB 3; TVL 9; Ap +1; Bp =1) and stress incontinence. She had undergone a previous vaginal repair in 2003. Urodynamic studies confirmed marked urodynamic stress incontinence. She requested surgery for her prolapse and stress incontinence and requested conservation of her uterus. She elected to undergo combined robotic and vaginal surgery. After robotic access was achieved, with the assistance of a uterine manipulator, the peritoneum anterior to the cervix is dissected transversely and reflected off the anterior cervix and upper anterior vaginal wall. The bladder is then reflected off the upper anterior vaginal wall. With the uterus anteverted, windows are created in the broad ligament on each side lateral to the uterus and above each uterine artery. The peritoneum over the sacral promontory is dissected to reveal the anterior longitudinal ligament on the sacral promontory. A tunnel under the peritoneum is created from sacral promontory to the sacral hollow. The peritoneum is dissected from the sacral hollow to the cul-de-sac.

A U-shaped synthetic graft (i.e. surgical mesh) is then introduced into the pelvis. The curved area of the U-shaped graft is placed on the anterior cervix and upper anterior vaginal wall. The straps of the graft are drawn through each of the broad ligament windows and then drawn through the peritoneal tunnel. The mesh straps are attached to the sacral promontory with non-absorbable

Free Communications - Digital Communications

Thursday 27 March 2014

mono-filament sutures. Any excess mesh above the sacral promontory fixation is trimmed and removed. The peritoneum below the peritoneal tunnel is either closed over, or approximated to, the mesh straps in order to avoid any bowel entrapment. Cystoscopy is routinely performed to exclude urinary tract injury. Concomitant colporrhaphy and TVT-Exact were performed.

SUMMARY: The novel approach to robotic sacral hysteropexy demonstrated in this video abstract potentially has significant advances over current techniques. This technique is likely to reduce the risk of recurrent uterine prolapse compared to current techniques. However, long-term clinical studies and comparative studies are required to confirm the effectiveness and safety of this procedure.

REFERENCES:

1. Am J Obstet Gynecol. 2003, 188; 108-15
2. BJOG. 2010 Jan; 117(1):62-8

AUTHOR AFFILIATION: S. Al-Salihi, M. Carey; The Royal Women's Hospital, Parkville, Victoria, Australia.

DIGITAL COMMUNICATIONS SESSION / 1240-1245

The first Australian robotic-assisted tubal anastomosis

Ang WC, Marshall B

Tubal occlusion by laparoscopy or laparotomy is a common method of achieving permanent contraception. It is common, especially in the younger population, to request a reversal due to the desire for more children. There are a variety of surgical techniques available to reverse the occlusion. Microsurgical anastomosis in open surgery was commonly performed in the past, until the use of in vitro fertilization and controlled ovarian hyperstimulation became more common in Australia.

The video describes the instrumentation and technique of the procedure using the Da Vinci robotic system. It also describes the methodology and approach to perform the novel approach, adapting techniques from the laparoscopic approach.

Although data is lacking, a Da Vinci robotic-assisted tubal anastomosis is considered to be advantageous in comparison to the open approach in cost and convalescence, and at least equal in outcomes to the laparoscopic approach.

REFERENCES:

1. Bedaiwy MA, Barakat EM, Falcone T. Robotic tubal anastomosis: technical aspects. JSLS 2011 Jan-Mar;15(1):10-15
2. Gala RB, Margulies R, Steinberg A, Murphy M, Lukban J, Jeppson P, et al. Systematic Review of Robotic Surgery in Gynecology: Robotic Techniques Compared with Laparoscopy and Laparotomy. J Minim Invasive Gynecol 2013 Dec 1
3. Weinberg L, Rao S, Escobar PF. Robotic surgery in gynecology: an updated systematic review. Obstet Gynecol Int 2011;2011:852061

AUTHOR AFFILIATION: W. C. Ang, B. Marshall; Royal Hospital for Women, Parkville, Victoria, Australia.

DIGITAL COMMUNICATIONS SESSION / 1245-1250

A robotic-assisted resection of Stage IV colorectal endometriosis

Ang WC, Bell S, Yao SE

Robotic assisted laparoscopic surgery continues to be of great interest to the surgical community with much debate regarding the best utilization, the cost-benefit analysis, and limits of its capabilities. Treating endometriosis with the Da Vinci robotic system was described in a retrospective controlled cohort study in 2010 in 78 patients. In early stage endometriosis, no difference in outcomes was observed. However, it was considered to be advantageous in severe endometriosis. Following this, there have small series published with a scarcity of long term data that demonstrate the feasibility and safety in using this approach.

This video presentation describes and discusses the advantages and disadvantages noted in planning and performing a resection of colorectal stage IV endometriosis in a young patient suffering pain and subfertility.

REFERENCES:

1. Carvalho L, Abrao MS, Deshpande A, Falcone T. Robotics as a new surgical minimally invasive approach to treatment of endometriosis: a systematic review. Int J Med Robot 2012 Jun;8(2):160-165
2. Ercoli A, D'asta M, Fagotti A, Fanfani F, Romano F, Baldazzi G, et al. Robotic treatment of colorectal endometriosis: technique, feasibility and short-term results. Hum Reprod 2012 Mar;27(3):722-726
3. Neme RM, Schraubman V, Okazaki S, Maccapani G, Chen WJ, Domit CD, et al. Deep infiltrating

Free Communications - Digital Communications

Thursday 27 March 2014

colorectal endometriosis treated with robotic-assisted resectosigmoidectomy. *JSL* 2013 Apr-Jun;17(2):227-234

4. Nezhat C, Lewis M, Kotikela S, Veeraswamy A, Saadat L, Hajhosseini B, et al. Robotic versus standard laparoscopy for the treatment of endometriosis. *Fertil Steril* 2010 Dec;94(7):2758-2760

AUTHOR AFFILIATIONS: W. C. Ang¹, S. Bell²; 1. Royal Women's Hospital, Parkville, Victoria, Australia. 2. The Alfred Hospital, Melbourne, Victoria, Australia.

DIGITAL COMMUNICATIONS SESSION / 1250-1255

Isolated sciatic nerve endometriosis: laparoscopic excision of a 3cm lesion

Chou D, de Rosnay P, Possover M, Cario G, Rosen D, Reyftmann L, Cook J, Choi S, Tsai B, McKenna J, Kanade J

Endometriotic lesions are commonly confined to the pelvic peritoneal cavity. Disease in retroperitoneal space affecting sciatic nerve is rare, especially when it is isolated in the absence of any peritoneal disease¹. We present a video presentation of laparoscopic excision of such a case in a healthy 24 years old nulligravid lady with severe menstrual sciatic pain. This young and fit lady has initially consulted Sport Physician and has had negative, X-Ray, Ultrasound and CT scan. Her MRI however detected a 3.4cm speculated lesion over her right sciatic nerve. Part of this lesion appeared to exit the pelvis through the greater sciatic foramen. There was evidence of injury to the superior gluteal nerve as there were denervation changes to the gluteus medius and minimus. Her case was extensively discussed with local specialist including gynaecological oncologist, neurosurgeon, trauma orthopaedic surgeon as well as world expert on such condition, Prof Marc Possover, from Zurich Switzerland by emails. The foreign and treacherous anatomy of the region was thoroughly reviewed preoperatively. Precautionary measures to minimise devastating complication in this area of major vascular and neural structures were extensively discussed.

REFERENCE:

1. Marc Possover, V Chiantera. Isolated infiltrative endometriosis of the sciatic nerve: a report of three patients. *Fertility and Sterility* Vol.87, No 2, Feb 2007

AUTHOR AFFILIATIONS: D. Chou¹, P. de Rosnay¹, M. Possover², G. Cario¹, D. Rosen¹, L. Reyftmann¹, J. Cook¹, S. Choi¹, B. Tsai¹, J. McKenna¹, T. Kanade¹; 1.Sydney Women's Endosurgery Centre, St George Private Hospital, Kogarah, New South Wales, Australia. 2.Possover International Medical Center, Zurich, Switzerland.

DIGITAL COMMUNICATIONS SESSION / 1255-1300

Non-puerperal uterine inversion due to endometrial carcinoma: Case report and review of the literature

Kapurubandara S, Hogg R

INTRODUCTION: Non puerperal uterine inversion due to endometrial carcinoma is a very rare condition with only a few cases reported in the existing literature^{1,2} Clinical diagnosis can be challenging and diagnosis is often made intra-operatively.

CASE REPORT: We illustrate a 64 year old Tongan patient with a 3 year history of post-menopausal bleeding presenting initially to emergency where she was discharged for outpatient assessment. Outpatient gynaecological review revealed a 6 cm mass distending the vagina on both speculum and pelvic examination. Biopsies of the mass were sent for histopathological evaluation but only revealed necrotic tissue. A gynaecological oncology referral was made and only a limited diagnostic evaluation was performed due to financial restrictions. Computed Tomography (CT) imaging confirmed a mass involving the uterus. She was booked for elective surgery but presented acutely with heavy vaginal bleeding requiring admission and blood transfusion. The patient underwent an emergency hysterectomy which revealed a grade 2 uterine inversion with an infected necrotic tumour extending into the vagina. A total abdominal hysterectomy, bilateral salpingo-oophorectomy and pelvic lymph node dissection was performed without repositioning the uterus and the specimen removed abdominally using a similar surgical technique as reported by Saxena et al.³ We will review the current literature including an evaluation of the available diagnostic work up and surgical options for the management of this rare gynaecological condition.

KEY WORDS: Non puerperal, endometrial cancer, uterine inversion, endometrial neoplasms

REFERENCES:

1. Oguri H, Maeda N, Yamamoto Y, et al. Non-puerperal uterine inversion associated with endometrial carcinoma – A case report. *Gynecologic Oncology* 2005; 97:973–975
2. Ueda K, Okamoto A, Yamada K, et al. Nonpuerperal inversion of the uterus associated with endometrial cancer: A case report. *Int J Clin Oncology* 2006; 11:153–155

Free Communications - Digital Communications

Thursday 27 March 2014

3. Saxena R, Shah T, Thirumalappa S et al. Technique of abdominal hysterectomy for non-peurperal uterine inversion. *BMJ Case report* 2011; 10: 1136/bcr.01.2011.3729

AUTHOR AFFILIATION: S. Kapurubandara, R. Hogg; Westmead Hospital, Westmead, New South Wales, Australia.

DIGITAL COMMUNICATIONS SESSION / 1300-1305

Laparoscopic retrieval of an intra-abdominal Mirena

Ratner R, Tsaltas J, Najjar H, Manley T

A 48 year old P4+1, with a history of one caesarean section, had a Mirena inserted for treatment of menorrhagia and premenstrual syndrome. Four months of abdominal discomfort prompted investigation for location of the Mirena as the strings were not visible on examination. A CT scan showed the IUD at the level of the umbilicus. The patient was referred for planning of localisation and laparoscopic removal of the Mirena. A repeat CT on the morning of the procedure to help with localisation, found the Mirena adjacent to the bladder.

In this presentation we will present this case, a literature review of management of lost IUDs, the CT images and video of the surgery.

AUTHOR AFFILIATION: R. Ratner, J. Tsaltas, H. Najjar, T. Manley; Monash Health, Clayton, Victoria, Australia.

DIGITAL COMMUNICATIONS SESSION / 1305-1310

Total laparoscopic hysterectomy made easier with new utero-vaginal manipulator

Titiz H

Hysterectomy is one of the common operations in gynaecology and laparoscopic hysterectomy has advantages such as shorter hospital stay, quicker recovery, less pain etc. compared to the abdominal hysterectomy.

Ideal uterine manipulator should have the following characteristics:

1. Able to offer range of movement of uterus including ante-version, retroversion, lateral movement, elevation of uterus;
2. Ability to delineate vaginal fornixes;
3. Maintain pneumoperitoneum;
4. Ability of being used only with vaginal manipulator

without inserting uterine manipulator when it is needed (eg cervical stenosis, cervix flushed with vaginal wall due to previous cervical operations, endometrial cancer);

5. Ability to manipulate vagina and uterus separately (it can be advantageous in some cases);
6. Ability to offer different size and shape manipulators according to patient needs and surgeon preference;
7. Ability to be versatile as it can also be used in other gynaecological operations;
8. Easy to assemble;
9. Cost effective and
10. Environmentally friendly.

Total laparoscopic hysterectomy can be done with this new utero-vaginal manipulator in 3 easy and safe steps. This utero-vaginal manipulator is reusable and it comes with vaginal part and uterine part. Vaginal part has different sizes and different tips. Tip of uterine part also comes with different length and shapes. Therefore surgeon can choose "right" parts according to surgeon preference, patient characteristics and type of operation.

This utero-vaginal manipulator can be used for the following operations:

1. Total laparoscopic hysterectomy
2. Supracervical (subtotal) laparoscopic hysterectomy
3. Laparoscopic assisted vaginal hysterectomy
4. Laparoscopic radical hysterectomy
5. Laparoscopic sacro-colpopexy
6. Laparoscopic sacro-hystero / colpopexy
7. Laparoscopic cerclage
8. For vaginal retrieval of fibroid, adnexal mass, lymph node etc.

This video demonstrates literature review of uterine manipulators, utero-vaginal manipulator parts, how to assemble it, and how to use it, videos of the cases manipulator being used, and summary of the initial data.

REFERENCES:

1. Mettler L et al A comparative survey of various uterine manipulators used in operative laparoscopy *Gynecol Surg* (2006) 3: 239-243
2. McCartney A et al Using vaginal tube to separate the uterus from the vagina during laparoscopic hysterectomy *Obstet Gynecol* (1995) 85 (2):293-296
3. Keriakos R et al The RUMI manipulator and Koh colpotomiser system for total laparoscopic hysterectomy *BJOG* 2000 107 (2):274-277

AUTHOR AFFILIATION: H. Titiz; Evin Women's Health, Stafford, Queensland, Australia.

Free Communications - Digital Communications

Thursday 27 March 2014

DIGITAL COMMUNICATIONS SESSION / 1310-1315

Tips and tricks on how to avoid injuries during laparoscopic sacro-colpo/hysteropexy

Titiz H

Pelvic organ prolapse is common in women and increases with age. The lifetime risk of undergoing prolapse or continence surgery is 9–11%¹. Abdominal sacrocolpopexy with mesh provides anatomic pelvic restoration, durable results, and less dyspareunia with 78-100% success rate². Laparoscopic sacrocolpopexy follows the same technique and produce the same results as abdominal sacrocolpopexy. In one of the review paper, the risks of injuries during abdominal sacrocolpopexy were:

Bladder injury: 3.1%, Small bowel and rectal injury: 1.6%, Bleeding: 4.4%, Ureteral injury: 1.0%²

In another review paper of 1197 combined cases, the risks of injuries during laparoscopic sacrocolpopexy were:

Bladder injury: 2.0%, Small bowel injury: 1.25%, Rectal injury: 0.4%, Bleeding: 1.1%, Ureteral injury: 0.08%¹

There are also 26 cases of pyogenic spondylodiscitis reported in the literature from 1957 to 2012³.

Vascular injury during dissection of promontory can cause life-threatening bleeding and is the reason for the nickname of 'sacro-scaropexy'. Small bowel injury can happen during abdominal and laparoscopic sacrocolpopexy and it can be missed 25 to 50% of time whether it is done abdominally or laparoscopically⁴. Small bowel injury has 20% mortality rate when it is not diagnosed intraoperatively.

This video demonstrates:

- History and evolution of sacrocolpopexy,
- Anatomic relation between midsacral promontory, left iliac vein, right common iliac artery, right ureter, L5-S1 disc
- Challenging cases of right aberrant branch from left iliac vein and very limited vessel-free area in sacral promontory due to anatomic variation of right common iliac artery and left common iliac vein
- Tips and tricks on:
 - How to safely dissect promontory
 - How to avoid and manage mid sacral artery bleeding
 - How to dissect right ureter when ureter is very close to right sacrouterine ligament
 - How to avoid bladder, small bowel and rectal injury and spondylodiscitis

REFERENCES:

1. Ganatra A. et al. The Current Status of Laparoscopic Sacrocolpopexy: A Review. *European Urology* 2009, 55: 1089-1105
2. Nygaard IE et al Abdominal Sacrocolpopexy: A Comprehensive Review *Am J Obst Gynecol* 2004, 104:805-823
3. Propst K et al Pyogenic spondylodiscitis associated with sacral colpopexy and rectopexy: report of two cases and evaluation of the literature *Int Urogynecol J* 2014, 25:21-31
4. Warner WB et al Intraoperative and Postoperative Gastrointestinal Complications Associated With Laparoscopic Sacrocolpopexy *Female Pelvic Med Reconstr Surg* 2012;18: 321Y324)

AUTHOR AFFILIATION: H. Titiz; Evin Women's Health, Stafford, Queensland, Australia.

DIGITAL COMMUNICATIONS SESSION / 1315-1320

Laparoscopic intramural myomectomy – recorded with 3D laparoscope

McKenna J, Tsai B, Kanade T, Choi S, Reyftmann L, Cario G, Rosen D, Chou D

Here we present a video recorded in 3D of a laparoscopic myomectomy of an 8cm intramural posterior fibroid. The patient is a 37-year-old nulligravid female who, without any previous surgical history, has symptoms of menorrhagia and abdominal discomfort. For advanced laparoscopic procedures such as intramural myomectomy that involve extensive suturing, the improved depth perception and high-definition images offered by 3D laparoscopes confer the benefits of superior spatial orientation and hand-eye coordination. This is an up-and-coming modality that will surely become the standard of care for advanced laparoscopy in the future.

REFERENCES:

1. Buchs NC and Morel P. Three-dimensional laparoscopy: a new tool in the surgeon's armamentarium. *Surg Technol Int.* 2013 Sep; 23:19-22
2. Lusch A et al. Evaluation of the impact of three-dimensional vision on laparoscopic performance. *J Endourol.* 2014 Jan 10 (Epub)

AUTHOR AFFILIATION: J. McKenna, B. Tsai, T. Kanade, S. Choi, L. Reyftmann, G. Cario, D. Rosen, D. Chou; Sydney Women's Endosurgery Centre, Kogarah, New South Wales, Australia.

Free Communications - Digital Communications

Thursday 27 March 2014

DIGITAL COMMUNICATIONS SESSION / 1320-1325

Robot-assisted hysterectomy – recorded in 3D

Tsai B, Kanade T, McKenna J, Choi S, Reyftmann L, Cario G, Rosen D, Chou D

Here we present a video recorded in 3D of a robot-assisted hysterectomy for benign disease. Since the advent of the da Vinci Surgical System, robot-assisted hysterectomy has become an increasingly popular form of minimally invasive gynaecologic surgery, especially in the United States. The uptake in Australia has somewhat lagged behind, especially in the area of benign gynaecologic disease. We have recorded this video in 3D to share our experience with robot-assisted hysterectomies. The 3D vision offered by the da Vinci robot is one of its innovative features, allowing for high-definition visualization and improved depth perception. Through this 3D video, we hope to recreate some of

the immersive surgeon console experience for the audience members while performing a robot-assisted hysterectomy. The degrees of freedom available with the robotic instrument arms are also demonstrated in clarity. This video will showcase how the robotic experience differs from conventional laparoscopy.

REFERENCES:

1. Bornhoft JM et al. Stereoscopic visualization and haptic technology used to create a virtual environment for remote surgery – biomed 2011. *Biomed Sci Instrum.* 2011;47:76-81
2. Rardin CR. The Debate over Robotics in Benign Gynecology. *Am J Obstet Gynecol.* 2014 Jan 10. Pii: S0002-9378(14)00029-5. [Epub ahead of print]

AUTHOR AFFILIATION: B. Tsai, T. Kanade, J McKenna, S. Choi, L. Reyftmann, G. Cario, D. Rosen, D. Chou; Sydney Women's Endosurgery Centre, Kogarah, New South Wales, Australia.

ROTOCUT™ G1 – The New Morcellator Generation

Extremely simple handling combined
with maximum power

STORZ
KARL STORZ – ENDOSKOPE

THE DIAMOND STANDARD

Free Communications - Digital Communications

Thursday 27 March 2014

DIGITAL COMMUNICATIONS SESSION / 1500-1505

Developing and implementing a mandatory evidence-based laparoscopy curriculum for residents at the Royal Women's Hospital

Connell F, Schreuder HWR, Van de Weijer P, Ang WC

STUDY OBJECTIVE: To develop and implement a validated laparoscopy curriculum for ITP trainees at the Royal Women's Hospital.

DESIGN: We developed a complete training curriculum including theoretical and practical components. The theoretical component encompasses basic core knowledge for laparoscopic surgery and the practical component requires the trainee to reach a level of proficiency on validated box trainer exercises¹. All level one to four trainees are mandated to attend teaching. Trainees must attain proficiency in the practical component in order to be primary operator during live surgery.

MEASUREMENTS: All level 1-4 registrars who had done a gynaecology rotation performed a right salpingectomy in live theatre (n= 23). This was recorded and will be blindly assessed using the OSA-LS, a validated assessment tool². A consultant-led lecture series was developed on a roughly fortnightly basis with practical training sessions immediately after. A validated series of 6 box trainer exercises was used with scores recorded for each trainee at each session. Attendance was also recorded. One year following initial live surgery. The level one registrars will be reassessed performing live salpingectomy. We describe our strategy and the pitfalls we encountered while implementing this mandatory laparoscopy curriculum in daily practice.

CONCLUSION: For patient safety and efficiency of training it is necessary that trainees have demonstrable practical laparoscopic skills before they start performing surgery on patients. A structured, mandatory, and evidence based laparoscopy curriculum aids us in reaching and monitoring this goal.

REFERENCES:

1. Schreuder HW, van den Berg CB, Hazebroek EJ, Verheijen RH, Schijven MP. Laparoscopic skills training using inexpensive box trainers: which exercises to choose when constructing a validated training course. *BJOG*. 2011 Dec;118(13):1576-84
2. Larsen CR, Grantcharov T, Schouenborg L, Ottosen C, Soerensen JL, Ottesen B. Objective assessment of surgical competence in gynaecological laparoscopy:

development and validation of a procedure-specific rating scale. *BJOG*. 2008 Jun; 115 (7):908-16

AUTHOR AFFILIATIONS: F. Connell¹, H. W. R. Schreuder², P. Van de Weijer², W. C. Ang¹; 1. The Royal Women's Hospital, Parkville, Victoria, Australia. 2. University Medical Centre Utrecht, Netherlands. 3. The University of Auckland, Waitemata Distr, New Zealand.

DIGITAL COMMUNICATIONS SESSION / 1505-1510

A retrospective review of all cases of leiomyosarcoma referred to The Royal Women's Hospital over a five-year period

Connell F, Gu Y, McNally O, Ang WC

BACKGROUND: Conventional teaching is that Uterine leiomyosarcoma is an extremely rare cancer, however there is compelling evidence that the rate is increasing¹. Laparoscopic myomectomy becomes increasingly an accepted procedure for fibroid treatment, however morcellation in the presence of an undetected sarcoma adversely affects disease free survival and overall survival rates².

AIM: To present the characteristics of the patients referred to The Royal Women's Hospital over a five-year period, and discuss the diagnostic dilemmas and implications of inadvertent morcellation.

RESULTS: The presenting symptoms of these twelve patients were abdominal pain, abnormal bleeding, abnormal mass, abdominal distension and "other" pain.

CONCLUSIONS: There are few reliably distinguishing features that highlight women with uterine sarcoma from women with benign fibroids. It is time to consider the pre-operative diagnostic tests available to us, and also the methods we use to extract fibroids.

REFERENCES:

1. Ueda SM, Kapp DS, Cheung MK, Shin JY, Osann K, Husain A, et al. Trends in demographic and clinical characteristics in women diagnosed with corpus cancer and their potential impact on the increasing number of deaths. *Am J Obstet Gynecol*. 2008 Feb;198(2):218 e1-6
2. Park JY, Park SK, Kim DY, Kim JH, Kim YM, Kim YT, et al. The impact of tumor morcellation during surgery on the prognosis of patients with apparently early uterine leiomyosarcoma. *Gynecol Oncol*. 2011 Aug;122(2):255-9

AUTHOR AFFILIATION: F. Connell, Y. Gu, O. McNally, W. C. Ang; The Royal Women's Hospital, Parkville, Victoria, Australia.

Free Communications - Digital Communications

Thursday 27 March 2014

DIGITAL COMMUNICATIONS SESSION / 1510-1515

Tuboovarian abscess as primary presentation for imperforate hymen

Wen Ho J, Angstetra D, Loong R, Fleming T

INTRODUCTION: Imperforate hymen represents an extreme in the spectrum of hymenal embryological variations, with reported incidence ranging from 0.014% to 0.1%. The archetypal presentation in the adolescent patient is that of cyclical abdominopelvic pain in the presence of amenorrhoea, however delay in diagnosis can result in more unusual presentations when the accumulated blood compresses adjacent pelvic organs or vessels.

CASE STUDY: A 14 year old virgin intact female patient presented to the emergency department complaining of severe left iliac fossa pain and heavy bleeding per vagina. This was her first episode of menstrual bleeding, however she reports cyclical pelvic pain for the prior three months. Examination revealed a septic patient with pyrexia, tachycardia and abdominal peritonism. External genital examination demonstrated a partially perforated hymen. Transabdominal ultrasound showed grossly dilated serpinginous fallopian tubes, and the upper part of vaginal was filled with homogeneous echogenic material. MRI elucidated the bilateral haematosalpinges, haematometra and haematocolpos. An examination under anaesthesia with planned operative laparoscopy was undertaken such that the imperforate hymen was opened via cruciate incision, and dense purulent intraabdominal material was evacuated laparoscopically prior to an incision and drainage of the persistent right tuboovarian abscess. Still images and video footage of this uncommon procedure were obtained.

CONCLUSION: Ideally, identification of imperforate hymen should occur during neonatal examination to prevent symptomatic presentation. Delay in diagnosis renders the potential for long term ramifications on reproduction and increases the risk for endometriosis. Our case highlights the risks of late recognition resulting in the rare complication of sepsis secondary to tuboovarian abscess.

AUTHOR AFFILIATION: J. Wen Ho, D. Angstetra, R. Loong, T. Fleming; The Gold Coast University Hospital, Department of Minimally Invasive Gynaecology, Southport, Queensland, Australia.

DIGITAL COMMUNICATIONS SESSION / 1515-1520

Laparoscopic management of adhesions from silent chemical peritonitis in a case of primary ovarian dermoid cyst

McKenna J, Kanade T, Tsai B, Choi S, Reyftmann L, Rosen D, Chou D, Cario G,

BACKGROUND: Dermoid cyst is the most frequent benign ovarian tumour. The cyst contents are known to cause significant pelvic adhesive disease, bowel obstruction, abdominal wall abscess and enterocutaneous fistula formation requiring the need for intensive medical and surgical management¹. Most of the case reports in such instances have been following spillage during surgical removal of the dermoid cyst. Spontaneous rupture with a silent chemical peritonitis is a rare consequence of ovarian cysts².

CASE: A 30 year old nulligravida presented with 1 month history of vague abdominal pain. The initial ultrasound was unremarkable. A repeat ultrasound showed left complex ovarian cyst of 58 mm x 48 mm with fluid around liver. An abdominal X-ray revealed teeth in the pelvis and a provisional diagnosis of left ovarian dermoid with a possibility of rupture was done. Patient had stable vitals, no complaints and examination was unremarkable. However, with clinical findings of perihepatic free fluid, patient was posted for urgent laparoscopic excision of dermoid cyst. Intraoperatively, patient had a left ovarian cyst with extensive hepatic adhesions. She had fatty material over the anterior wall and pelvis, suggestive of a silent rupture in the past. The ovary was densely adherent to the pelvic wall. There were also a few endometriotic deposits on the pelvic wall which were excised and sent for histopathological examination. The dense perihepatic adhesions were carefully separated. Reports from the hepatic adhesions and cyst confirmed benign cystic teratoma. Patient was well in the immediate post-operative period. After four months follow up, patient had some right sided pain. Repeat laparoscopy showed mild endometriotic deposits and fatty hepatic adhesions. Excisional surgery and lavage was repeated. Since then patient follow up has been uneventful.

CONCLUSION: Spontaneous rupture resulting in silent chemical peritonitis is an unusual presentation of dermoid cysts. Identification of subtle signs followed by diagnosis and treatment by laparoscopy form the optimum treatment in such cases.

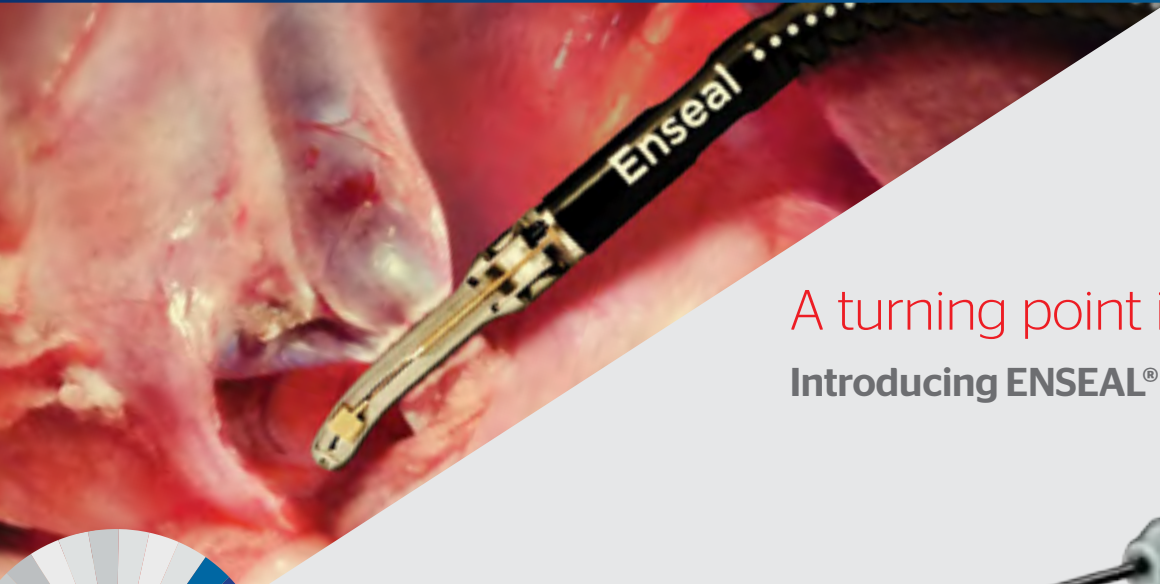Free Communications - Digital Communications

Thursday 27 March 2014

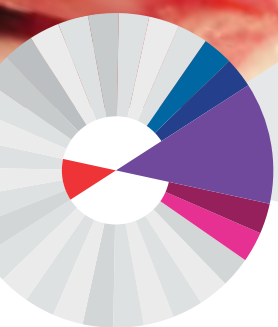
REFERENCES:

1. Clemont D, Barranger E, Bechimol Y, Uzan S. Chemical peritonitis: a rare complication of an iatrogenic ovarian dermoid cyst rupture. *Surg Endosc.* 2003;17:658
2. Da Silva BB, dos Santos AR, Lopes-Costa PV, Sousa-Júnior EC, Correa-Lima MV, Pires CG. Ovarian dermoid cyst with malignant transformation and rupture of the capsule associated with chemical peritonitis: a case report and literature review. *Eur J Gynaecol Oncol.* 2009;30(2):226-8

AUTHOR AFFILIATION: T. Kanade, J. McKenna, B. Tsai, S. Choi, L. Reyftmann, D. Rosen, D. Chou, G. Cario; Sydney Women's Endosurgery Centre, Kogarah, New South Wales, Australia.



A turning point in vessel sealing
Introducing **ENSEAL® G2 Articulating**



For more information on our products please call customer service in Australia on 02 9815 4278 or 1800 252 194 and in New Zealand on 0800 803 988.

AUSTRALIA: Johnson & Johnson Medical Pty Ltd, 1-5 Khartoum Road, North Ryde, NSW 2113.

NEW ZEALAND: Johnson & Johnson (New Zealand) Ltd, 507 Mt Wellington Highway, Mt Wellington, Auckland 1060.

ETHICON

PART OF THE **Johnson & Johnson** FAMILY OF COMPANIES

FR5126/02/14 E201310_190

Better surgery for a better world

Enseal

Free Communications - Digital Communications

Friday 28 March 2014

DIGITAL COMMUNICATIONS SESSION / 1030-1035

Robotic Burch colposuspension: rise of the machines!

Kanade T, McKenna J, Tsai B, Choi S, Reyftmann L, Chou D, Rosen D, Cario G

INTRODUCTION: The rapid adoption of robotic technology stems from the enhanced visualization, wristed instrumentation, and improved ergonomics inherent to such systems, enabling more surgeons to perform minimally invasive procedures previously restricted to surgeons with advanced laparoscopic skills¹. The first published report of robotic Burch colposuspension was in 2007². The oral presentation demonstrates the background, anatomy, and surgical technique of robotically-assisted laparoscopic Burch colposuspension.

CASE: 42 year old multigravida presented with stress urinary incontinence for 2 years and frequency and urgency since 1 year. Urodynamics showed a positive stress profile with pelvic organ prolapse quantification (POP-Q) showing a stage II anterior wall prolapse. Ultrasound showed descent in the bladder neck. She was posted for Total Laparoscopic hysterectomy with B/L salpingectomy with Burch colposuspension and paravaginal repair. Patient opted for the robotic assisted technique when asked/ proposed/ suggested. The hysterectomy and salpingectomy were uneventful with an operative time of 55 mins. The retropubic space of Retzius was opened and dissected up till the pelvic floor. The bladder neck and mid urethra were localised easily. Bladder neck and paravaginal V-loc sutures were placed from the Cooper's ligament through the vaginal fornix and back to Cooper's ligament ad locked. The total operative time was 145 mins. The colposuspension was for 90 mins. The pelvic access for suture placement was challenging, indicating a need for more experience in the field. Patient was passing urine well on trial of void and discharged on day 2.

CONCLUSION: The robotically-assisted laparoscopic Burch colposuspension represents a safe alternative to transvaginal sling procedures, and is especially well-suited to combined procedures in which robotic assistance is already contemplated. With paucity in available literature defining specifics for upcoming surgeries and research is challenging.

REFERENCES:

1. Gala RB, Margulies R, Steinberg A, Murphy M, Lukban J, Jeppson P, Aschkenazi S, Olivera C, South M, Lowenstein L, Schaffer J, Balk EM, Sung V, A

Systematic Review Of Robotic Surgery In Gynecology – Robotic Techniques Compared With Laparoscopy And Laparotomy, The Journal of Minimally Invasive Gynecology (2013), doi: 10.1016/j.jmig.2013.11.010

2. Khan MS, Challacombe BJ, Rose K, Dasgupta P (2007) Robotic Colposuspension: two case reports. J Endourol 21 (9): 1077-1079

AUTHOR AFFILIATION: T. Kanade, J. McKenna, B. Tsai, S. Choi, L. Reyftmann, D. Chou, D. Rosen, G. Cario; Sydney Women's Endosurgery Centre, Kogarah, New South Wales, Australia.

DIGITAL COMMUNICATIONS SESSION / 1035-1040

Bone in the uterus

Kong K, Kanade T, Tsai B, McKenna J, Choi S, Reyftmann L, Rosen D, Cario G, Chou D

This is a video presentation of hysteroscopic retrieval of endometrial ossification and literature review on osseous metaplasia of the endometrium.

Patient was a 37 years old nulliparous lady who had a history of miscarriage and termination of pregnancy. She underwent laparoscopy and laparotomy for recurrent pelvic inflammatory disease 10 years ago.

Patient was asymptomatic and planning to conceive via IVF. Routine pelvic ultrasound showed highly echogenic structure within the uterine cavity, which raise the possibility of osseous metaplasia of endometrium. On hysteroscopy, a piece of coral like bony tissue was retrieved with flexible hysteroscopic grasper. Histopathology of the specimen showed fragments of woven and lamellar bone intimately associated with the endometrial tissue. Haematopoiesis was noted within the bony spaces.

Endometrial ossification is a rare condition and has potential negative effect on fertility¹. Patients reported a range of symptoms, such as menstrual irregularities, pelvic pain, dyspareunia, vaginal discharge and the passage of bony fragments in menstrual blood, whereas some patients were asymptomatic².

The etiology of heterotopic bone in the endometrium remains controversial. There are two most widely accepted hypothesis; the retention of embryonic bones on a background history of miscarriage or termination of pregnancy, and osseous metaplasia of endometrial tissue².

In conclusion, our case demonstrates the importance of considering endometrial ossification as a cause of infertility in patients with a history of pelvic inflammatory disease

Free Communications - Digital Communications

Friday 28 March 2014

and termination of pregnancy. Diagnosis and treatment of endometrial ossification with hysteroscopy could restore fertility and encourage spontaneous conception.

REFERENCES:

1. Gulec UK, Parlakgumus HA, Kılıçdağ EB, Bolat F, Bagis T. Osseous metaplasia of the endometrium. *BMJ Case Rep.* 2010 Aug 19; 2010
2. Basu M, Mammen C, Owen C. Bony fragments in the uterus: an association with secondary subfertility. *Ultrasound Obstet Gynecol.* 2003; 22: 402-406

AUTHOR AFFILIATION: K. Kong, T. Kanade, B. Tsai, J. McKenna, S. Choi, L. Reyftmann, D. Rosen, G. Cario, D. Chou; Sydney Women's Endosurgery Centre (SWEC), St George Private Hospital, Kogarah, New South Wales, Australia.

DIGITAL COMMUNICATIONS SESSION / 1040-1045

Combining mini-laparotomy and laparoscopy for the large ovarian cyst – a retrospective case series

Li T, Tan J, Gannon E

OBJECTIVE: Laparoscopy has become an integral component of gynaecological surgery for apparent advantages such as smaller incisions, shorter hospital stay and earlier return to daily activities of living. However, for large ovarian masses, laparotomy remains the preferred method due to concerns for malignancy, risk of cyst rupture, limitations of surgical field and difficulty in specimen retrieval. This retrospective case series aims to discuss the technique utilised by the Gynaecological Oncologist Consultant – Dr. Jason Tan, which incorporates a mini-laparotomy and laparoscopy. Outcomes such as histopathology findings, length of hospital stay and patient satisfaction will be discussed.

METHODS: A total of 17 patients were selected by Dr. Jason Tan from both King Edward Memorial Hospital and St John of God Hospital Subiaco from the period between June 2012 and September 2013. The patient's history, tumour markers and imaging were carefully reviewed to ensure that there was minimal to low risk for malignancy before they were considered suitable for the procedure. The mini-laparotomy incision aided in the downsizing of the cyst and specimen retrieval, and the rest of operation was performed laparoscopically. The patient case files were subsequently reviewed, and outcomes such as length of hospital stay, post-operative pain score, pain score on discharge and histopathology results were looked at. In addition, a feedback evaluation of the patient's experience is also included in this study.

RESULTS: The mean age of the patients was 52 years old (+/- 23 years old) and Body Mass Index (BMI) was 29.6kg/m² (+/- 8.4kg/m²). The mean size of the cyst was 22cm (+/- 6.8cm) which is important to highlight as most studies considered 10 cm and above to be large. Out of the 17 cases, fourteen were found to be benign on histopathology while three of the cases were Stage 1C Borderline Mucinous tumour. These 3 cases were optimally debulked, and did not require adjuvant chemotherapy. The 3 cases were staged as a 1C as the cyst was downsized prior to a cystectomy or oophorectomy. The average length of hospital stay was 2.8 days (+/- 1.4 days). With regards to pain score on Day 1 post-operative, the mean was 2.3 (+/- 2.1) on a scale of 1 to 10 (with 10 as having severe pain). The mean pain score on discharge was 1.8 (+/- 1.4 days).

CONCLUSION: The combination of using mini-laparotomy and laparoscopy for the removal of large ovarian cyst is a feasible surgical technique provided it is being utilised in appropriate patients with thorough pre-operative workup. This is however a small retrospective case series and could be expanded further to include more patients and to incorporate the patients' long-term outcomes.

REFERENCES:

1. Yi SW. Minimally invasive management of huge ovarian cysts by laparoscopic extracorporeal approach. *Minimally Invasive Therapy.* 2012;21:429-434
2. Stavroulis A, Memtsa M, Yoong W. Methods for specimen removal from the peritoneal cavity after laparoscopic excision. *The Obstetrician & Gynaecologist.* 2013;15:26-30
3. Goh SM, Yam J, Loh SF, Wong A. Minimal access approach to the management of large ovarian cysts. *Surg Endosc.* 2007;21:80-83

AUTHOR AFFILIATION: T. Li, J. Tan, E. Gannon; King Edward Memorial Hospital, Subiaco, Western Australia, Australia.

DIGITAL COMMUNICATIONS SESSION / 1045-1050

Laparoscopic management of late acute vault abscess & irreducible vault eversion 3 years after anterior mesh repair

McKenna J, Kanade T, Tsai B, Reyftmann L, Chou D, Rosen D, Cook J, Cario G

A 60year old lady underwent bilateral sacrospinous ligament fixation and anterior vaginal mesh repair for complete vault eversion. She had previously undergone a total laparoscopic hysterectomy and posterior laparoscopic

Free Communications - Digital Communications

Friday 28 March 2014

vaginal mesh repair. Three years later she presented with an acute and irreducible complete vault eversion, associated with acute urinary retention and lower abdominal with pelvic pain.

She required admission and an examination under anaesthesia was performed. Pus was extruding from the site of the ulcer on the vault but no focal lesion of mesh erosion was found. At laparoscopy the bladder was noted to be adherent to the vaginal vault over a large area but there was no evidence of intra-abdominal infection or chronic abscess. Under general anaesthesia the prolapse remained irreducible and was confirmed to be extruding pus. A 10cm deep abscess cavity was drained and debrided. The cavity was left open to drain and heal by primary intention. The urinary catheter was left in situ for one month. Intravenous antibiotic therapy was commenced and continued for three months. Vaginal management of her complete vault eversion was not possible. Definitive treatment of this complication was achieved with laparoscopic sacral colpopexy, utilising the previously placed mesh as the distal component of the new mesh repair.

This case represents an unusual presentation of mesh complication. The patient presented with an acute infective abscess three years after the vaginal mesh was placed. A possible triggering event was postulated to be an endoscopy performed a few days prior to her presentation.

A review of the literature confirms the atypical nature of this complication and its subsequent management. Typical complications of this procedure are usually mesh erosion, pain or dyspareunia. Vaginal surgical management is often the surgical management option of choice. Vaginal excision of mesh is usually effective in cases of mesh erosion, but only resolves symptoms in half of patients presenting with pain(1). Late abscess is usually seen in the context of a chronically infected mesh which necessitates removal of the mesh, again often affecting cure by means of a vaginal approach(2) and often rendering the patient, once again symptomatic of her primary prolapse complaint. Using advanced laparoscopic skills this patient was able to have definitive treatment without the need for removal of the previously sited mesh repairs.

REFERENCES:

1. Uncommon complications of sacrospinous fixation for treatment of vaginal vault prolapse, Silva-Filho AL et al, Arch Gynecol Obstet. 2005 Apr; 271(4):358-62
2. Sacrospinous ligament fixation for eversion of the vagina, Morley GW & DeLancey JO, AM J Obstet Gynecol. 1988 Apr;158 (4):872-81

3. Long-term follow-up after vaginal sacrospinous fixation: patient satisfaction, anatomical results and quality of life, Aigmuller T et al, Int Urogynecol J Pelvic Floor Dysfunct. 2008 Jul;19 (7):965-9

AUTHOR AFFILIATION: J. McKenna, T. Kanade, B. Tsai, S. Choi, L. Reyftmann, D. Chou, D. Rosen, J. Cook, G. Cario; Sydney Women's Endosurgery Centre, Kogarah, New South Wales, Australia.

DIGITAL COMMUNICATIONS SESSION / 1050-1055

To evaluate the role of pre-operative Transvaginal Ultrasound (TVS) to predict appropriate surgical route for the management of women with adnexal mass

Menakaya UA, Reid S, Shetty Y, Infante FI, Lu C, Condous G

OBJECTIVES: To evaluate the role of pre-operative transvaginal ultrasound (TVS) to predict appropriate surgical route for the management of women with adnexal mass.

METHODS: Prospective observational study. Each woman had a detailed preoperative TVS performed by an experienced sonologist to assess the adnexal mass. Each lesion was classified using the IOTA protocol and the most likely histological diagnosis predicted using pattern recognition.

At TVS, the most appropriate surgical route was predicted (laparoscopy vs. laparotomy). If the adnexal mass was deemed to be benign (regardless of diameter), then the woman was scheduled for laparoscopic intervention. Prediction of the laparoscopic route was deemed successful if the intention to treat was successfully completed laparoscopically.

RESULTS: One hundred and eight women with adnexal masses were analysed. Based on the IOTA classification, 78.7% (85/108) of adnexal masses were classified as benign, 8.3% (9/108) borderline and 13% (14/108) malignant. The mean diameter of the adnexal masses was 84 mm (range 11 – 360 mm).

Pre-operative TVS successfully predicted the intention to treat laparoscopically with an accuracy of 97.2%, sensitivity 96.4%, specificity 100%, positive predictive value (PPV) 100% and negative predictive value (NPV) 88.5%.

Pre-operative prediction of benignity, borderline and malignancy gave an accuracy 88% - 86.1% - 96.3%,

Free Communications - Digital Communications

Friday 28 March 2014

sensitivity 93.9% - 28.6% - 91.7%, specificity 69.2% - 94.7% - 96.9, PPV 90.6% - 44.4% - 78.6% and NPV 78.3% - 89.8% - 98.9%, respectively.

AUTHOR AFFILIATIONS: U. A. Menakaya¹, S. Reid², Y. Shetty¹, F. I. Infante¹, C Lu³, G Condous¹; 1.Acute gynaecology, early pregnancy and advanced endoscopic unit Nepean Hospital, Penrith, New South Wales, Australia. 2.Royal Hospital for Women, Randwick, New South Wales, Australia. 3.Department of Computer Sciences, University of Wales, Aberystwyth, United Kingdom.

DIGITAL COMMUNICATIONS SESSION / 1230-1235

Prediction of pod obliteration using the real time dynamic sliding sign - a review of 200 cases undergoing laparoscopy

Menakaya UA, Reid S, Lu C, Infante FI, Condous G

OBJECTIVE: To evaluate the accuracy of the real time dynamic sliding sign in the prediction of POD obliteration - a review of 200 cases

METHOD: A prospective evaluation of 200 patients who had laparoscopic surgery for endometriosis over a 5-year period. All patients underwent a preoperative transvaginal ultrasound.

The preoperative transvaginal ultrasound included an assessment of the POD using the real time dynamic sliding sign. At laparoscopy, the status of the POD was also recorded. Both the transvaginal ultrasound preoperative findings and the findings at laparoscopy were collated and analysed. The prediction of POD obliteration using the sliding sign was evaluated in the first 100 women and the performance of the test was compared to the second 100 women - ALL cases were subject to the same gold standard laparoscopic POD findings.

RESULTS: The accuracy, sensitivity, specificity, PPV and NPV for predicting POD obliteration in the first 100 cases in our series was 94%, 83.9% 98.6%, 96.3% and 93.2%

The accuracy, sensitivity, specificity, PPV and NPV for predicting POD obliteration in the later 100 cases in our series was 98%, 100% 97.5%, 90.9% and 100%

CONCLUSION: Since our first publication in 2012, the performance of our unit has improved when it comes to prediction of POD obliteration.

AUTHOR AFFILIATIONS: U. A. Menakaya¹, S. Reid², C Lu³, F. I. Infante¹, G Condous¹; 1.Acute gynaecology, early pregnancy and advanced endoscopic unit Nepean

Hospital, Penrith, New South Wales, Australia. 2.Royal Hospital for Women, Randwick, New South Wales, Australia. 3.Department of Computer Sciences, University of Wales, Aberystwyth, United Kingdom.

DIGITAL COMMUNICATIONS SESSION / 1235-1240

In women with normal POD and no posterior compartment deep infiltrating endometriosis, can we use the soft marker, site-specific tenderness at TVS, in the pre-operative mapping of peritoneal endometriosis

Reid S, Menakaya U, Lu C, Infante FI, Condous G

OBJECTIVES: To determine whether the presence of site-specific tenderness during TVS corresponds with the location of peritoneal endometriosis at surgery for women with suspected endometriosis.

METHODS: Multi-centre prospective observational study undertaken from January 2009 to February 2013. This study included women with symptoms of chronic pelvic pain +/- history of endometriosis, planned for laparoscopic endometriosis surgery. All women underwent pre-operative TVS, where site-specific tenderness was elicited by placing gentle pressure with the TV probe against each of the six locations: anterior fornix, right adnexa, left adnexa, right uterosacral ligament (RUSL), left USL, and posterior fornix. Women rated their pain score from 0 (no pain) to 10 (worst pain) for each of the six locations. All women underwent laparoscopy +/- excision of endometriosis. Those women with either an endometrioma and/or posterior compartment deep infiltrating endometriosis at laparoscopy were excluded from the analysis, i.e. only those women with peritoneal disease were included. The relationship between site-specific tenderness at TVS and location of peritoneal endometriosis at surgery was then analysed.

RESULTS: 189 consecutive women with TVS and laparoscopic outcomes were included in the final analysis. 100 women were found to have isolated peritoneal endometriosis. Peritoneal endometriosis was present in the following locations at surgery: left USL (39%), right USL (33%), left pelvic sidewall (30%), right pelvic sidewall (23%), pouch of Douglas (POD) (22%), uterovesical pouch (14%), left pararectal space (9%), right pararectal space (6%), and posterior cervix (4%). The only positive association between site-specific tenderness at TVS and peritoneal endometriosis location at surgery was for site-specific tenderness at the posterior vaginal

Free Communications - Digital Communications

Friday 28 March 2014

fornix and the presence of peritoneal endometriosis in the POD ($p=0.0486$).

CONCLUSIONS: The use of site specific tenderness during TVS appears to be useful in the mapping of peritoneal endometriosis involving the POD.

AUTHOR AFFILIATIONS: S. Reid², U. A. Menakaya¹, C Lu³, F. I. Infante¹, G Condous¹; 1.Acute gynaecology, early pregnancy and advanced endoscopic unit Nepean Hospital, Penrith, New South Wales, Australia. 2.Royal Hospital for Women, Randwick, New South Wales, Australia. 3.Department of Computer Sciences, University of Wales, Aberystwyth, United Kingdom.

DIGITAL COMMUNICATIONS SESSION / 1240-1245

Platelet rich plasma and CO2 laser treatment of vaginal atrophy and dyspareunia: a pilot study

Behnia-Willison F, Miller B, O'Shea R, Seman E, Turnbull L, Rezaei-Motlagh A

AIMS: To present patient satisfaction data 6 to 12 months following treatment with platelet rich plasma (PRP) and/or CO2 laser treatment of vaginal atrophy and/or dyspareunia.

BACKGROUND: PRP is an autologous concentrate of human platelets in a small volume of plasma. It is rich in protein growth factors. It has been used for improving wound healing in plastic and reconstructive surgery, and in sports medicine.^{1,2}

CO2 laser with a fractionated beam is used in cosmetic medicine as an "anti-aging" treatment. Promotional literature states that it stimulates the production of collagen and improves blood flow in epithelial tissue.

PRP and CO2 laser have been evaluated and found to improve vaginal atrophy on histology.³

METHODS: The women received 1-3 treatments of either intradermal PRP and/or superficial CO2 laser ablation. PRP was prepared on site & injected randomly into vaginal dermis at multiple sites, from the hymen to the fornices. Fractionated, CO2 laser was applied to the entire vagina using a specially designed vaginal probe. A short animation is included to illustrate these processes.

Women were phone interviewed by an independent researcher 6-12months after completing a course of treatment for either indication.

RESULTS: Of 47 women treated in 2012 & 2013 with CO2 laser for vaginal atrophy, 24 responded: 4 felt cured, 14 felt improvement, 3 experienced no effect, 2 improved then relapsed, and 1 felt treatment made her worse.

Of 11 women treated with laser for dyspareunia, 7 responded: 3 felt improved, 2 cured, and one experienced no effect.

Of 7 women treated with PRP for vaginal atrophy, 5 responded: 3 felt improved, 1 improved then relapse, and 1 experienced no effect.

Of 15 women treated with both PRP and laser for vaginal atrophy, 11 responded: 5 felt cured, 3 felt improved, 2 improved then relapsed, and 1 experienced no effect.

Of 5 women treated with both PRP and laser for dyspareunia, 4 responded: 3 felt cured and 1 had improved symptoms.

DISCUSSION: Overall, the majority of women interviewed reported an improvement in symptoms. A further study of treatment of vaginal atrophy is planned using the following outcome measures: rates of dyspareunia, vaginal pH, vaginal cytology (maturation index), the Australian pelvic floor questionnaire, vaginal exam (looking for stenosis, absent rugae, petechiae and friability of the vaginal wall) and side effects of treatment.

REFERENCES:

1. Eppley BL, Pietrzak WS, Blanton M. Platelet-rich plasma: A review of biology and applications in plastic surgery. *Plastic and reconstructive surgery*. 2006. 118(6): 147-159.
2. Forster T, Puskas BL, Mandelbaum BR, Gerhardt MB, Rodeo S. Platelet-rich plasma from basic science to clinical applications. *The American Journal of Sports Medicine* 2009. 37(11): 2259-2272.
3. Gaspar A, Gaddamo G, Brandi H. Vaginal fractional CO2 laser: a minimally invasive option for vaginal rejuvenation. *American Journal of Cosmetic Surgery*. 2011. 28(3): 156-162.

AUTHOR AFFILIATION: F. Behnia-Willison, B. Miller, R. O'Shea, E. Seman, L. Turnbull, A. Rezaei-Motlagh; Endogynaecology Unit, Flinders Medical Centre.

DIGITAL COMMUNICATIONS SESSION / 1245-1250

Women's attitudes and expectations towards trans-vaginal NOTES from East to West

Behnia-Willison F, Johns K, Behnia L, Mirzakhani P, Jourabchi A, Sarmadian M, Garg A, Miller B, Rezaei-Motlagh A

AIMS: To present women's views across the cultures on NOTES as a minimally invasive surgery

Free Communications - Digital Communications

Friday 28 March 2014

BACKGROUND: Trans-vaginal natural orifice transluminal endoscopic surgery (NOTES) is a recently developed minimally invasive surgical procedure, aimed at minimising scars, pain and reducing recovery times. Although the trans-vaginal NOTES technique has been studied with respect to outcomes of postoperative pain and cosmesis, the acceptance of the technique by women has only been cursorily examined. This is a vital process when a new technique involves an intimate part of the anatomy that holds strong personal, religious and cultural significance. In this study, the acceptance of the technique was assessed from a cohort of women from Iran, a culturally sensitive background.

MATERIALS AND METHODS: 175 Persian women were surveyed using a twelve-item questionnaire at a single gynaecology centre. The survey used was a translated version of a questionnaire from a previous study¹. The questionnaire was designed to collect demographic information from each woman, as well as their view with regards to trans-vaginal NOTES.

RESULTS AND DISCUSSION: The data collected was compiled, presented as percentages and analysed with the appropriate statistical assessments. A univariate assessment was performed on the trans-vaginal view questions, indicating that Persian women collectively did have opinions on this topic. The data was subsequently assessed in a bivariate manner to determine any relationships between the demographics of the women assessed and their view towards trans-vaginal NOTES. It was found that Persian women are not fully accepting of the use of the vagina as a peritoneal entry site. Among the interesting findings, it was found that older women and those who already had children were more likely to be happy with a trans-vaginal approach, while sexual implications and the gender of the surgeon were identified as concerns of Persian women. We will compare this data with our Australian study on Notes.

CONCLUSIONS: The present paper analysed the attitudes of Persian women towards trans-vaginal NOTES and found that, despite its inherent invasiveness, the technique may hold value even for women with a traditional Middle-Eastern cultural upbringing. This study provides surgeons with information regarding women's perspective of the trans-vaginal NOTES approach, which may be of considerable clinical use as the surgical technique becomes more prevalent.

REFERENCES:

1. A. Strickland, M. Norwood and F. Behnia-Willison, "Transvaginal natural orifice transluminal endoscopic

surgery (NOTES): a survey of women's view on a new technique," *Surg Endosc*, pp. 2424-2431, 2010

2. Patient Perceptions of Natural Orifice Transluminal Surgery. *Minimally Invasive Surgery Volume 2012*, Article ID 317249, 7 pages doi:10.1155/2012/317249
3. P. Bucher, S. Osterman, F. Pugin et al., "Female population perception of conventional laparoscopy, transumbilical LESS, and transvaginal NOTES for cholecystectomy," *Surgical Endoscopy*, vol. 25, no. 7, pp. 2308-2315, 2011

AUTHOR AFFILIATIONS: F. Behnia-Willison¹, K. Johns², L. Behnia³, P. Mirzakhani⁴, A. Jourabchi², M. Sarmadian^{5,6}, A. Garg², B. Miller¹, A. Rezei- Motlagh²; 1. Endogynaecology Unit, Flinders Medical Centre, Bedford Park, Queensland, Australia. 2. Flinders University, Bedford Park, South Australia, Australia. 3. Alameh Tabatabaie University, Tehran, Iran. 4. Department of Education and Psychology, Semnan University, Semnan, Iran. 5. Queen Elizabeth Hospital, Woodville, South Australia, Australia. 6. Adelaide University, North Terrace, South Australia, Australia.

DIGITAL COMMUNICATIONS SESSION / 1250-1255

Management of major haemorrhage and conversion to open surgery at laparoscopic hysterectomy

Muttusamy T, Qin V, Merkur H

BACKGROUND: The main intra-operative complications specific to laparoscopic hysterectomy include haemorrhage (2.0%), urological injury (0.5%), conversion to laparotomy (3.3%) or vaginal approach (2.0%)¹. Published complications rates have progressively fallen as surgeons' surgical experience has improved over time. For laparoscopic hysterectomy, major intraoperative haemorrhage can be defined as blood loss at the time of hysterectomy that necessitates conversion to abdominal or vaginal hysterectomy. Post-operative bleeding as defined in the CREST study is any bleeding event that requires intervention, invariably a return to the operating theatre². Major haemorrhage is often considered one of the main factors for conversion to open surgery.

OBJECTIVE: To identify the main causes of haemorrhage at laparoscopic hysterectomy and its management options. To determine whether haemorrhage was a major cause for conversion to open surgery at laparoscopic hysterectomy.

METHOD: This is a retrospective cohort study over three years involving 780 patients operated at a large

Free Communications - Digital Communications

Friday 28 March 2014

laparoscopic unit, involving 15 laparoscopic surgeons, both in public and private practice.

RESULTS: 35 patients had conversions from laparoscopic hysterectomy to laparotomy or laparoscopic assisted vaginal hysterectomy. Less than 30% of conversions to open surgery had haemorrhage as the major indication. Other reasons for conversion were more common and included fibroids, adhesions and large uterine size.

CONCLUSION: Given the vast improvements in the techniques used for laparoscopic hysterectomy, the overall conversion rates from laparoscopic hysterectomy are low. Haemorrhage, whilst being a prominent reason for conversion, it is not the commonest.

REFERENCES:

1. Canis M, Botchorishvili R, Ang C et al. When is laparotomy needed in hysterectomy for benign uterine disease. *JMIG* 2008;15(1):38
2. Harris, Wesley J. Early Complications of abdominal and vaginal hysterectomy. *Obstet Gynecol Surv*:1995 Nov;50(11):795-805

AUTHOR AFFILIATION: T. Muttusamy, V. Qin, H. Merkur; Sydney West Advance Pelvic Surgery Unit, Western Sydney Local Health District, New South Wales, Australia.

DIGITAL COMMUNICATIONS SESSION / 1255-1300

Invasive Group A streptococcus infection in O and G patients at Sydney metropolitan hospitals

Qin V, Wong C, Blumenthal N, Hardas G, Nikam Y, Yang V, Merkur H, Haghighi K

OUTLINE: Group A streptococcal (GAS, *Streptococcus pyogenes*) infection is an infrequent, but potentially lethal infection in women. An increasing prevalence of severe GAS infection has been reported, predominantly in North America.

In Australia, we are encountering more cases of invasive GAS infection in practices of obstetrics and gynaecology. Invasive GAS infection still causes 40% of septic deaths among patients with postpartum endometritis, necrotizing fasciitis, and toxic shock syndrome. Often, the symptoms and signs of this infection are nonspecific.

A total of 3 cases of severe invasive GAS infection were reviewed at Sydney metropolitan hospitals over 2012 and 2013 retrospectively. All patients had Group A streptococcus confirmed on microbiology including

blood culture and wound swabs. They all had different clinical presentations and antecedent events, but required immediate surgical intervention and prolonged admission to intensive care. Multidisciplinary management is mandatory for their management, including prompt surgical debridement and appropriate antibiotics treatment.

A brief review of literature regarding GAS and obstetrics and gynaecology is included. Awareness of this lethal infection is necessary as we are seeing more cases across Sydney.

REFERENCES:

1. Rimawi B, Soper D, Eschenback D. Group A Streptococcal Infections in Obstetrics and Gynecology. *Clin Obstet Gynec* 2012;55(4):864-874
2. Stevens DL. Streptococcal toxic-shock syndrome: spectrum of disease, pathogenesis, and new concepts in treatment. *Emerg Infect Dis* 1995;1:69

AUTHOR AFFILIATIONS: V. Qin¹, C. Wong^{1,2}, N. Blumenthal¹, G. Hardas¹, Y. Nikam¹, V. Yang^{1,2}, H. Merkur H¹, K. Haghighi³; 1.Sydney West Advance Pelvic Surgery Unit, Western Sydney Local Health District, New South Wales, Australia. 2.Royal Prince Alfred Hospital, Camperdown, New South Wales, Australia. 3.Prince of Wales Hospital, Randwick, New South Wales, Australia.

DIGITAL COMMUNICATIONS SESSION / 1300-1305

Major vascular injury at laparoscopy: do we need a surgical drill?

Qin V, Merkur H

OUTLINE: Major vascular injury in gynaecologic laparoscopy is rare with a reported incidence 0.1 to 1.0%. Majority of injury occurs at port entry for surgical access, and the rest at surgical dissection. Much of the medical literature and research have concentrated on the prevention of vascular injury to achieve safe port entry. Yet there are few guidelines available when the surgeon faces life-threatening vascular injury in a very stressful situation.

A recent case has prompted our unit to contemplate the need for a surgical 'drill' for laparoscopic major vascular injury. This patient has sustained injury to the inferior epigastric artery at time of hysterectomy and removal of endometriosis which necessitated bowel resection. While the decision for quick laparotomy was easy, getting

Free Communications - Digital Communications

Friday 28 March 2014

appropriate surgical equipment was challenging when the situation was highly stressful for everyone in operating theatre.

We have identified several aspects to formulate a surgical 'drill' to major vascular injury. Anaesthetist will provide appropriate resuscitation when the blood loss is rapid. Adequate direct pressure can stop the bleeding while awaiting expert help from vascular surgeon. Getting the right surgical equipment will help to expedite the repair and optimise the outcome. Our unit will consider trialling such surgical drill on yearly basis in conjunction with theatre staff and general surgeons.

REFERENCE:

1. Chapron CM, Pierre F, Lacroix S et al. Major vascular injuries during gynecologic laparoscopy. *J Am Coll Surg* 1997;185(5):461
2. Ahmad G, Duff JM, Phillips K. Laparoscopic entry techniques. *Cochrane Database Syst Rev* 2008;CD006583
3. Sandadi S, Johannigma JA, Wong VL et al. Recognition and management of major vessel injury during laparoscopy. *JMIG* 2010;17(6):692

AUTHOR AFFILIATION: V. Qin, H. Merkur; Sydney West Advance Pelvic Surgery Unit, Western Sydney Local Health District, New South Wales, Australia.

DIGITAL COMMUNICATIONS SESSION / 1305-1310

Decrease in AMH after laparoscopic excision of endometrioma

Rodgers R, Reid G, Cooper M, Tsaltas J

Laparoscopic excision of endometriomas is considered the gold standard treatment in terms of reducing pelvic pain, dysmenorrhea and dyspareunia, and in improving fertility outcome. It is also associated with the lowest rate of recurrence.

An observational study of women with endometriosis-related infertility by Barri et al (2010) reported a significant advantage of surgical excision of endometriomas over IVF and conservative management. Of the 483 women who underwent laparoscopic excision of endometrioma, 54.2% conceived spontaneously, and a cumulative pregnancy rate of 65.8% was achieved when women who did not spontaneously conceive were offered IVF. This is in comparison to a 32.2% pregnancy rate for women who underwent IVF without prior excision, and an 11.8% pregnancy rate over 8 years in women who opted for no intervention.

Excision of an endometrioma is unavoidably associated with a degree of damage to the ovary and, for women with already low ovarian reserve, this is an important pre-operative consideration. Indeed, the excision of endometriomas in older women with minimal ovarian reserve for the purposes of improving fertility, may be counterproductive – if post-operative conception does not occur spontaneously, response to ovarian stimulation for the purpose of IVF may be inadequate, and thus fertility assistance options limited.

Quantifying the degree of damage to the ovary associated with the excision of endometrioma is therefore crucial. Several recent studies have attempted to quantify the degree to which ovarian reserve is diminished by excision of endometrioma. Methods used include pre- and post-operative measurement of anti-mullerian hormone (AMH), follicle stimulating hormone (FSH), oestradiol (E2) and ultrasound markers such as antral follicle count (AFC). Of these, AMH is generally considered the most useful and reliable marker.

A systematic review by Somigliana et al (2012) reported a statistically significant decrease in pre- and post-operative AMH levels in nine of eleven included studies of women undergoing surgical excision of endometrioma. A study by Celik et al (2012) reported decreases of 26% and 61% respectively between pre-operative AMH levels and levels taken six weeks and six months post-operatively. AMH levels at six months had significantly decreased (67% decrease) more in women who had bilateral endometriomas resected. Interestingly, AMH decreased by more than half (57%) in women undergoing unilateral endometrioma resection.

This presentation will outline the experience of three Australian advanced laparoscopic surgeons in relation to the effect of excision of endometrioma has on the ovary, in terms of pre- and post-operative AMH values.

REFERENCES:

1. Barri PN, Coroleu B, Tur R, Barri-Soldevila PN, Rodriguez I (2010) *Endometriosis-associated infertility: surgery and IVF, a comprehensive therapeutic approach*, *Reproductive BioMedicine Online*, 21, pp 179-185
2. Celik HG, Dogan E, Okyay E, Ulukus C, Saatli B, Uysal S, Koyuncuoglu M (2012) *Effect of laparoscopic excision of endometriomas on ovarian reserve: serial changes in the serum antimullerian hormone levels*, *Fertility and Sterility*, 97(6), pp 1472-1478
3. Somigliana E, Berlanda N, Benaglia L, Vignani P, Vercellini P, Fedele L (2012) *Surgical excision of*

Free Communications - Digital Communications

Friday 28 March 2014

endometriomas and ovarian reserve: a systematic review on serum antimullerian hormone level modifications, Fertility and Sterility, 98(6), pp 1531-1538

AUTHOR AFFILIATIONS: R. Rodgers¹, G.Reid^{2,3,4,5}, M.Cooper^{3,6,7}, J Tsaltas⁸; 1.Royal Prince Alfred Hospital, Camperdown, New South Wales, Australia. 2.Genea / Liverpool, New South Wales, Australia. 3.St Luke's Hospital, Pott's Point New South Wales, Australia., 4.St George Private, Kogarah, New South Wales, Australia. 5.Southern Highlands Private Hospital, Bowral, New South Wales, Australia. 6.Genea / RPA, Camperdown, New South Wales, Australia., 7.St Vincent's, Darlinghurst, New South Wales, Australia. 8.Melbourne IVF, Victoria, Australia.

DIGITAL COMMUNICATIONS SESSION / 1310-1315

A horn too many – the total laparoscopy in the management of uterine anomalies

Thevathasan I, Myers C, De Luca L, Sherwood R

Paucity exists in the literature in regards to the management of symptomatic uterine anomalies by total laparoscopic hysterectomy. We present a case series of two uterine anomalies (uterine didelphys bicollis and rudimentary uterine horn) managed with total laparoscopic hysterectomy at Sunshine Hospital.

The case history of each patient will be described in detail. We will describe the pre-operative management of patients with uterine anomalies including the use of Magnetic Resonance Imaging and Renal Tract Ultrasound to correctly identify the anatomy prior to the operation. The intra-operative management of each case will be discussed in detail with visual aids and pay particular attention to the operative difficulties encountered, the need for specialised equipment and specific laparoscopic techniques utilised during the operation. Finally, we will discuss the post-operative course including any complications encountered and results of a six week follow up appointment.

AUTHOR AFFILIATION: I. Thevathasan, C. Myers, L. De Luca, R. Sherwood: Sunshine Hospital, St Albans, Victoria, Australia.

DIGITAL COMMUNICATIONS SESSION / 1315-1320

Effect of obesity on outcomes in gynaecological laparoscopic procedures

Wong WL, Ho JW, Fleming T

AIM: To evaluate the effect of obesity, defined as Body Mass Index of ≥ 30 (BMI, calculated as weight in kilograms divided by the square of height in meters) on the perioperative outcomes among patients who underwent gynaecologic laparoscopic procedures.

DESIGN: Retrospective cohort study

SETTING: Department of Obstetrics and Gynaecology, Gold Coast Hospital

MATERIALS AND METHODS: In a retrospective cohort study at the Gold Coast Hospital, data was compared from 213 patients who underwent gynaecologic laparoscopic procedures, which included diagnostic laparoscopy, laparoscopic cystectomy, oophorectomy, salpingectomy, salpingotomy, bilateral tubal ligation and excision of endometriosis, and total laparoscopic hysterectomy (TLH). For each procedure, patients were divided into two groups: non-obese (BMI < 30) and obese (BMI ≥ 30). Selected primary outcomes were anaesthetic time, operative time, conversion to laparotomy, length of stay (LOS), estimated blood loss $>250\text{ml}$ (EBL), operative and postoperative complications. These findings were then added to the available worldwide data for a formal meta-analysis.

RESULTS: In our study, it was shown that the obese group had a statistically significantly longer operative time when compared to the non-obese group (OR=1.915, $p=0.024$). However, there is no statistically significant differences between the two groups in terms of anaesthetic time (OR=1.365, $p=0.276$), LOS (OR=1.588, $p=0.107$), rate of EBL $>250\text{ml}$ (OR=0.169, $p=0.088$), procedure conversion (OR=2.981, $p=0.443$), operative (OR=0.731, $p=0.782$) and postoperative complication rate (OR=0.661, $p=0.530$).


The meta-analysis revealed that the overall blood loss was increased for those patients with a BMI ≥ 30 (OR=1.342, $p = 0.007$) and those women were also likely to have operative complications (OR=2.028, $p=0.002$), and procedure conversion (OR=1.789, $p=0.006$). Furthermore, operative time (OR=1.641, $p<0.0001$), and LOS (OR=1.186, $p=0.054$) are prolonged in the BMI ≥ 30 group. Interestingly, the meta-analysis showed that women with a BMI < 30 were more likely to suffer postoperative complications (OR=0.640, $p=0.009$).

Free Communications - Digital Communications

Friday 28 March 2014

CONCLUSIONS: Obese women undergoing gynaecological laparoscopic procedures were found to have an elevated risk of intraoperative complications including blood loss and procedure conversion, in addition to an increased length of hospital stay and operative time. Of interest, women with normal BMI were demonstrated to have a heightened rate of postoperative complications.

AUTHOR AFFILIATION: W. L. Wong, J. W. Ho, T. Fleming; The Gold Coast University Hospital Department of Minimally Invasive Gynaecology, Southport, Queensland, Australia.



AGES MEETINGS in 2014



**AGES Pelvic Floor
Symposium & Workshop XV**
Pelvic Floor Surgery - Going Native
Adelaide
15 & 16 August 2014



**AGES / RANZCOG
Trainee Workshop X 2014**
Brisbane
13 & 14 September 2014



**AGES Focus Meeting
Complications**
Perth
24 & 25 October 2014

Sponsors

AGES gratefully acknowledges the following sponsors:

stryker®

Stryker is one of the world's leading medical technology companies and is dedicated to helping healthcare professionals perform their jobs more efficiently while enhancing patient care. The Company offers a diverse array of innovative medical technologies, including reconstructive, medical and surgical, and neurotechnology and spine products to help people lead more active and more satisfying lives.

For more information on Stryker, please visit www.stryker.com

Sponsors



As a new generation medical device company, Applied Medical is proud to provide innovative surgical products that improve patient outcomes and enable the advancement of minimally invasive surgery.

Our dedication to understanding and satisfying our customers' needs has made Applied a leading provider of breakthrough technologies and clinical advancements for Minimally Invasive Surgery, including the Alexis® wound protectors/retractors and GelPOINT® advanced access platforms.

Applied is also committed to helping surgeons remain at the forefront of the latest techniques in Minimally Invasive Surgery. Our Master Class Workshops, Simsei® laparoscopic trainer and high-fidelity simulation platform allow surgeons to enhance their skill sets and attain hands-on experience.

To learn more, please visit www.appliedmedical.com or call 1800 666 272



Device Technologies is a major supplier of leading edge medical devices to hospitals and healthcare professionals throughout Australia and New Zealand.

The da Vinci Si surgical system System features:

- Advanced 3D HD visualisation with up to 10x magnification and an immersive view of the operative field
- EndoWrist® instrumentation with dexterity and range of motion far greater than even the human hand
- Intuitive® motion technology, which replicates the experience of open surgery by preserving natural eye-hand-instrument alignment and intuitive instrument control
- A fully customizable and ergonomic interface, ensuring reduced surgeon fatigue

Together, these technological advancements provide surgeons with unparalleled precision, dexterity and control that enable a minimally invasive approach to many complex surgical procedures.

There are currently 22 active da Vinci® sites across Australia and New Zealand. If you would like more information please contact

E: davinci@device.com.au M +61 438 811 393 W www.device.com.au

Heath Priestly
General Manager - da Vinci Surgery



Since its beginnings in 1945, KARL STORZ has established itself worldwide as an international and highly regarded company in the production and sale of endoscopic devices, documentation and cameras. KARL STORZ Endoscopy Australia is a wholly owned affiliate of KARL STORZ GmbH and the parent company remains owned by the STORZ family. The majority of manufacturing is carried out in Tuttlingen, Germany where the art of instrument making is alive and well.

KARL STORZ Endoscopy Australia can further support a wide spectrum of emerging markets such as Neuroendoscopy, Orthopaedics, Anaesthesiology, General Surgery, Plastics, Cardiovascular, Thoracoscopy, Gastroenterology, Spinal, MTP single use accessories as well as our already established markets such as Urology, ENT, Gynaecology and Laparoscopy.

KARL STORZ Endoscopy Australia also supports the sale of new endoscopes, instruments, fiberscopes and videoscopes with a Service Programme which is the only Comprehensive Endoscopic Management Programme in the market place. The new one capped pricing model for rigid scopes and the four Tier classing system for fiberscopes and videoscopes ensures that your inventory stays at it optimal condition with it's built in technology upgrades and Preventative Care & Maintenance.

Visit the KARL STORZ booth and talk to the experts to find out more about the complete KARL STORZ range.



Ethicon is part of Johnson & Johnson Medical Pty Ltd (JJM), the leading provider of medical devices to the Australian and New Zealand health care systems. The company is part of the Johnson & Johnson Family of Companies, one of the world's most comprehensive health care organizations, and our origins date back to 1955.

JJM has a longstanding commitment to the Gynaecological Community through our range of products that specialise in wound closure; women's health and urology; minimally invasive technology including laparoscopic instruments and mechanical staplers; sterilization; hand hygiene and decontamination.

We live by our vision of 'Caring for the world, one person at a time...' Our Credo is at the heart of what we do every day and reminds us of our responsibilities to our patients; doctors and nurses; our employees; our community and the environment and our shareholders.

We were founded on a purpose beyond profit and have a meaningful Corporate Social Responsibility Program. We support programs that improve health and well-being through our community partners and proudly sponsor surgical missions throughout the Asia-Pacific region

CONFERENCE INFORMATION AND CONDITIONS

Deposits and final payments:

All Conference costs are payable in advance. If, for any reason, your entire payment has not been received by the due date, we reserve the right to treat your booking as cancelled and will apply the appropriate cancellation fees.

Faxed or posted registration forms will only be processed/confirmed if valid credit card details or cheque payment accompany the forms. You may not pay your fees by Electronic Funds Transfer.

Cancellation and Refund Policy:

Should you or a member of your party be forced to cancel, you should advise the Conference Organisers in writing addressed to AGES, 282 Edinburgh Road, Castlecrag NSW 2068 Australia.

Single Meeting Registrations: the Conference cancellation policy allows a cancellation fee of AU\$250.00 of registration fees for cancellations received up to 8 weeks prior to the first day of the Conference, and of 50% of registration fees for cancellations up to 4 weeks prior to the first day of the Conference. No refund will be made after this time.

Multiple Meeting Registrants: no refunds apply.

Hotels and other suppliers of services, depending on date of cancellation, may also impose cancellation charges. Accommodation payments will be forfeited if the room is not occupied on the requested check-in date. Please note that a claim for reimbursement of cancellation charges may fall within the terms of travel insurance you effect.

The Conference Organisers reserve the right to cancel any workshop or course if there are insufficient registrations. Also, at any time, without notice and without giving reasons, the Conference Organisers may cancel or postpone the Conference, change the venue or any published timetables, activities, presenters or particulars without being liable for any loss, damage or expense incurred or suffered by any person.

Refunds of the whole or any part of the fees and payments received by the Conference Organisers will only be made if the Conference Organisers in the exercise of their absolute discretion, determine that persons have been unfairly prejudiced by any cancellation, postponement or change.

Insurance:

Registration fees do not include insurance of any kind. It is strongly recommended that at the time you register for the Conference and book your travel you take out an insurance policy of your choice. The policy should include loss of fees/deposit through cancellation of your participation in the Conference, or through cancellation of the Conference, loss of international/domestic air fares through cancellation for any reason, loss of tour monies through cancellation for any reason including airline or related services strikes within and/or outside Australia, failure to utilise tours or pre-booked arrangements due to airline delay, force majeure or any other reason, medical expenses (including sickness and accident cover), loss or damage to personal property, additional expenses and repatriation should travel arrangements have to be altered. The Conference Organisers cannot take any responsibility for any participant failing to arrange his/her own insurance. This insurance is to be purchased in your country of origin.

Pricing policy:

It is impossible to predict increases to cost elements such as government taxes and other service provider tariffs. In the event of such fluctuations or increases affecting the price of the Conference, we reserve the right to adjust our prices as may be necessary at any time up to and including the first date of the Conference, even though the balance payment may have been made.

If we are forced to change your booking or any part of it for any reason beyond our control – for instance, if an airline changes its schedule – we

reserve the right to vary your itinerary and will give you, or cause to be given to you, prompt notice thereof.

Conference costs do not include: Insurance, telephone calls, laundry, food and beverage except as itemised in the brochure, and items of a personal nature.

Travel and Accommodation:

The Conference Organisers are not themselves carriers or hoteliers nor do we own aircraft, hotels, or coaches. The flights, coach journeys, other travel and hotel accommodation herein are provided by reputable carriers and hoteliers on their own conditions. It is important to note, therefore, that all bookings with the Conference Organisers are subject to terms and conditions and limitations of liability imposed by hoteliers and other service providers whose services we utilise, some of which limit or exclude liability in respect of death, personal injury, delay and loss or damage to baggage.

Our responsibility:

The Conference Organisers cannot accept any liability of whatever nature for the acts, omissions or default, whether negligent or otherwise of those airlines, coach operators, shipping companies, hoteliers, or other persons providing services in connection with the Conference pursuant to a contract between themselves and yourself (which may be evidenced in writing by the issue of a ticket, voucher, coupon or the like) and over whom we have no direct and exclusive control.

The Conference Organisers do not accept any liability in contract or in tort (actionable wrong) for any injury, damage, loss, delay, additional expense or inconvenience caused directly or indirectly by force majeure or other events which are beyond our control, or which are not preventable by reasonable diligence on our part including but not limited to war, civil disturbance, fire, floods, unusually severe weather, acts of God, act of government or any authorities, accidents to or failure of machinery or equipment or industrial action (whether or not involving our employees and even though such action may be settled by acceding to the demands of a labour group). Please note that add prices quoted are subject to change without notice.

Privacy:

Collection, maintenance and disclosure of certain personal information are governed by Australian legislation. Please note that your details may be disclosed to the parties mentioned in this brochure and your details may be included in the list of delegates.

Entry to Australia:

All participants from countries outside Australia are responsible for complying with Australian visa and entry requirements and re-entry permits to their own countries. Letters to support visa applications will be sent upon request, but only after receipt of registration forms and fees.

Conference Badges:

Official name badges must be worn or produced on demand at all times during the Conference to obtain entry to all Conference sessions and to social functions. Proof of identity will be required for the issue of replacement badges.

The Conference Organisers:

References to 'the Conference Organisers' in the above Conference Information and Conditions mean Australasian Gynaecological Endoscopy and Surgery Society Limited ACN 075 573 367, Michele Bender P/L trading as Conference Connection ACN 03 402 328, and if the context requires, each of them severally.